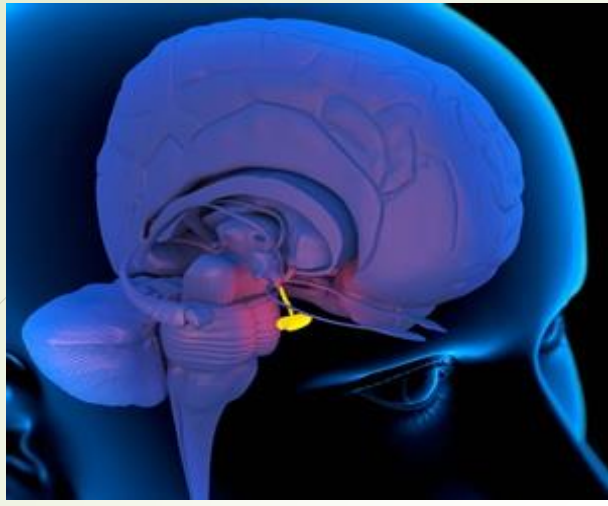



**BRIEF ACCOUNT OF STRUCTURAL
FEATURES HISTOLOGICAL STRUCTURE
AND FUNCTION OF ENDOCRINE
GLANDS –
PITUITARY, THYROID, PANCREAS,
ADRENAL AND GONADS**

BY: DR. LUNA PHUKAN



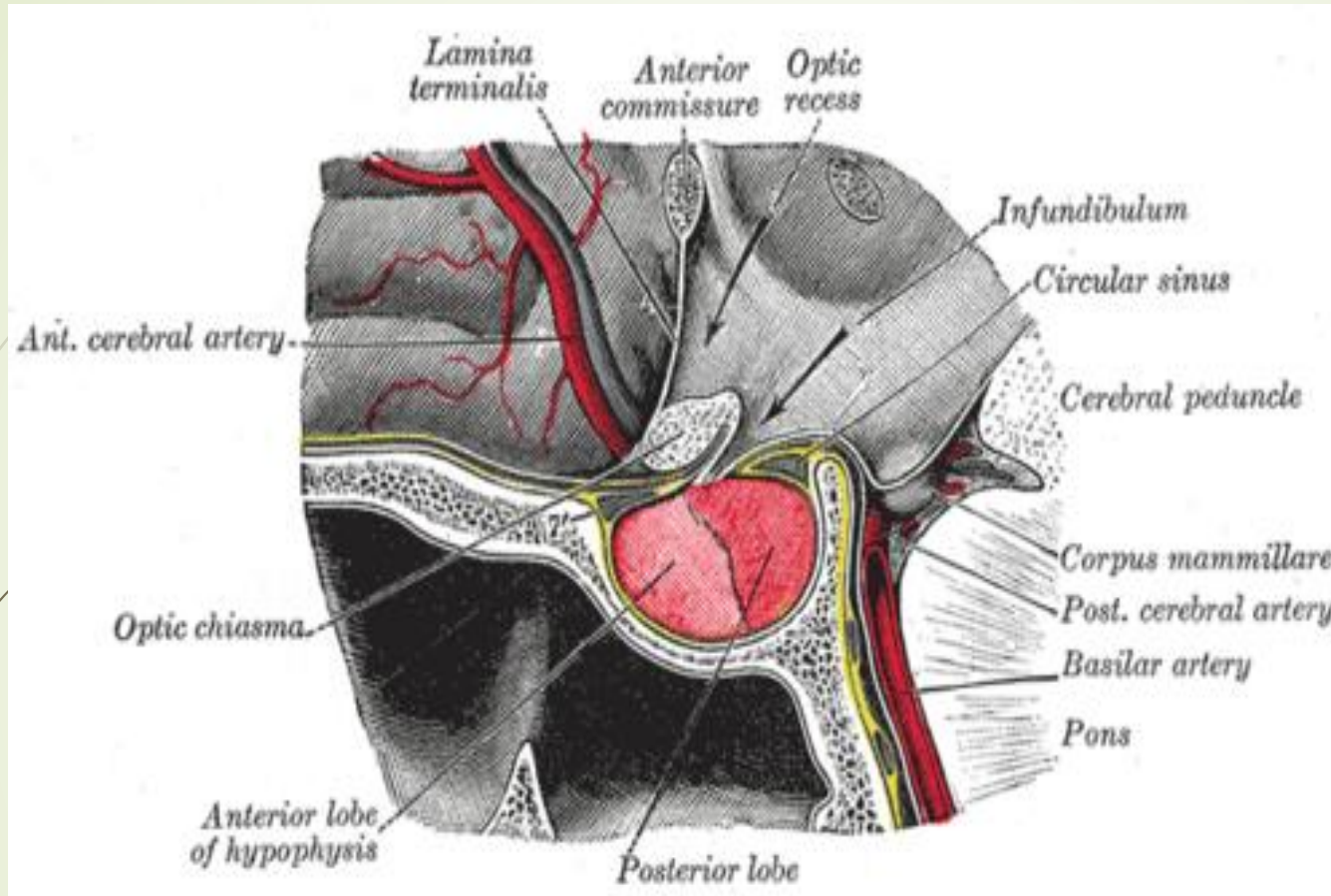
**BRIEF ACCOUNT OF
STRUCTURAL FEATURES
HISTOLOGICAL STRUCTURE AND
FUNCTION OF PITUITARY GLAND**



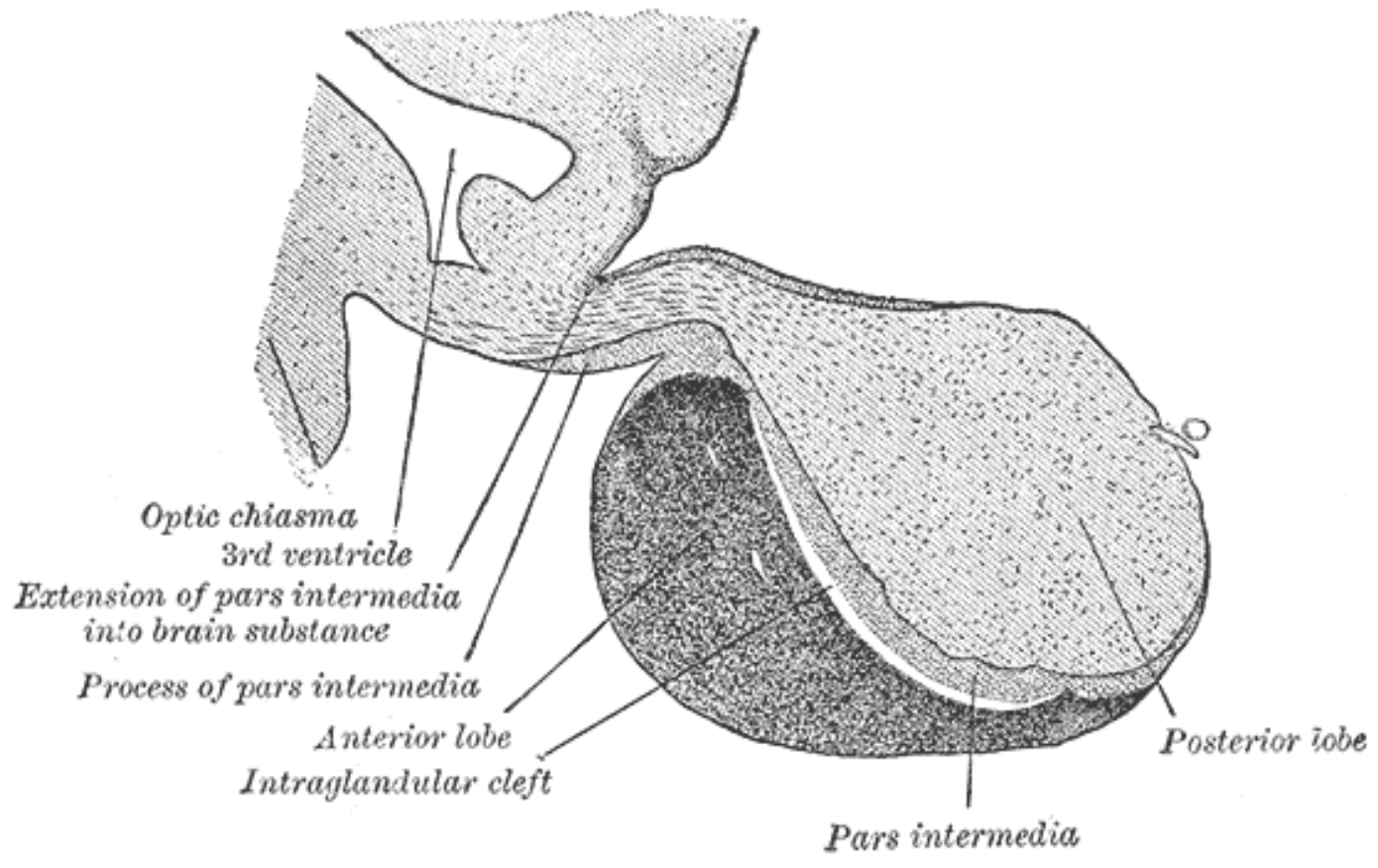
Endocrine glands are ductless glands of the endocrine system that secrete their products, hormones, directly into the blood.

The major glands of the endocrine system include the pineal gland, pituitary gland, pancreas, ovaries, testes, thyroid gland, parathyroid gland, hypothalamus and adrenal glands.

The hypothalamus and pituitary glands are neuroendocrine organs.



Located at the base of the brain, the pituitary gland is protected by a bony structure called the sella turcica of the sphenoid bone.




In vertebrate anatomy, the pituitary gland, or hypophysis, is an endocrine gland, about the **size of** a pea and weighing 0.5 grams (0.018 oz) in humans. It is a protrusion off the bottom of the hypothalamus at the base of the brain. The hypophysis rests upon the hypophysial fossa of the sphenoid bone in the center of the middle cranial fossa and is surrounded by a small bony cavity (sella turcica) covered by a dural fold (diaphragma sellae).

The anterior pituitary (or adenohypophysis) is a lobe of the gland that regulates several physiological processes (including stress, growth, reproduction, and lactation).

The intermediate lobe synthesizes and secretes melanocyte-stimulating hormone.

The posterior pituitary (or neurohypophysis) is a lobe of the gland that is functionally connected to the hypothalamus by the median eminence via a small tube called the pituitary stalk (also called the infundibular stalk or the infundibulum).



Hormones secreted from the pituitary gland help to control growth, blood pressure, energy management, all functions of the sex organs, thyroid glands and metabolism as well as some aspects of pregnancy, childbirth, breastfeeding, water/salt concentration at the kidneys, temperature regulation and pain relief.

Structure

The pituitary gland, in humans, is a pea-sized gland that sits in a protective bony enclosure called the sella turcica. It is composed of two lobes: anterior and posterior, with the intermediate lobe that joins the two regions. In many animals, these three lobes are distinct. The intermediate is avascular and almost absent in human beings.

The intermediate lobe is present in many animal species, in particular in rodents, mice and rats, that have been used extensively to study pituitary development and function.

In all animals, the fleshy, glandular anterior pituitary is distinct from the neural composition of the posterior pituitary, which is an extension of the hypothalamus

Anterior pituitary


The anterior pituitary arises from an invagination of the oral ectoderm (Rathke's pouch). This contrasts with the posterior pituitary, which originates from neuroectoderm.

Endocrine cells of the anterior pituitary are controlled by regulatory hormones released by parvocellular neurosecretory cells in the hypothalamic capillaries leading to infundibular blood vessels, which in turn lead to a second capillary bed in the anterior pituitary. This vascular relationship constitutes the hypothalamo-hypophyseal portal system.

Diffusing out of the second capillary bed, the hypothalamic releasing hormones then bind to anterior pituitary endocrine cells, upregulating or downregulating their release of hormones.

The anterior lobe of the pituitary can be divided into the pars tuberalis (pars glandularis) and pars distalis (pars glandularis) that constitutes ~80% of the gland. The pars intermedia (the intermediate lobe) lies between the pars distalis and the pars tuberalis, and is rudimentary in the human, although in other species it is more developed.[4] It develops from a depression in the dorsal wall of the pharynx (stomal part) known as Rathke's pouch.

The anterior pituitary contains several different types of cells[6] that synthesize and secrete hormones. Usually there is one type of cell for each major hormone formed in anterior pituitary. With special stains attached to high-affinity antibodies that bind with distinctive hormone, at least 5 types of cells can be differentiated.



Sl.No.	Type of cell	Hormone secreted	Percentage of type of cell
1.	Somatotropes	human growth hormone (hGH)	30-50%
2.	Corticotropes	adrenocorticotropin (ACTH)	20%
3.	Thyrotropes	thyroid stimulating hormone (TSH)	3–5%
4.	Gonadotropes	gonadotropic hormone i.e., both luteinizing hormone (LH) and follicle stimulating hormone (FSH)	3–5%
5.	Lactotropes	prolactin (PRL)	3–5%

Posterior pituitary

The posterior lobe develops as an extension of the hypothalamus, from the floor of the third ventricle. The posterior pituitary hormones are synthesized by cell bodies in the hypothalamus. The magnocellular neurosecretory cells, of the supraoptic and paraventricular nuclei located in the hypothalamus, project axons down the infundibulum to terminals in the posterior pituitary. This simple arrangement differs sharply from that of the adjacent anterior pituitary, which does not develop from the hypothalamus. The release of pituitary hormones by both the anterior and posterior lobes is under the control of the hypothalamus, albeit in different ways

Anatomy and Histology of the Pituitary Gland

The pituitary gland or hypophysis is derived from two embryologically-distinct tissues. As such, it is composed of both neural and glandular tissue. Both tissues produce hormones that affect a large number of physiological processes.

Prior to embarking on the lessons below, it would be best to review the core section **Functional Anatomy of the Hypothalamus and Pituitary Gland**.

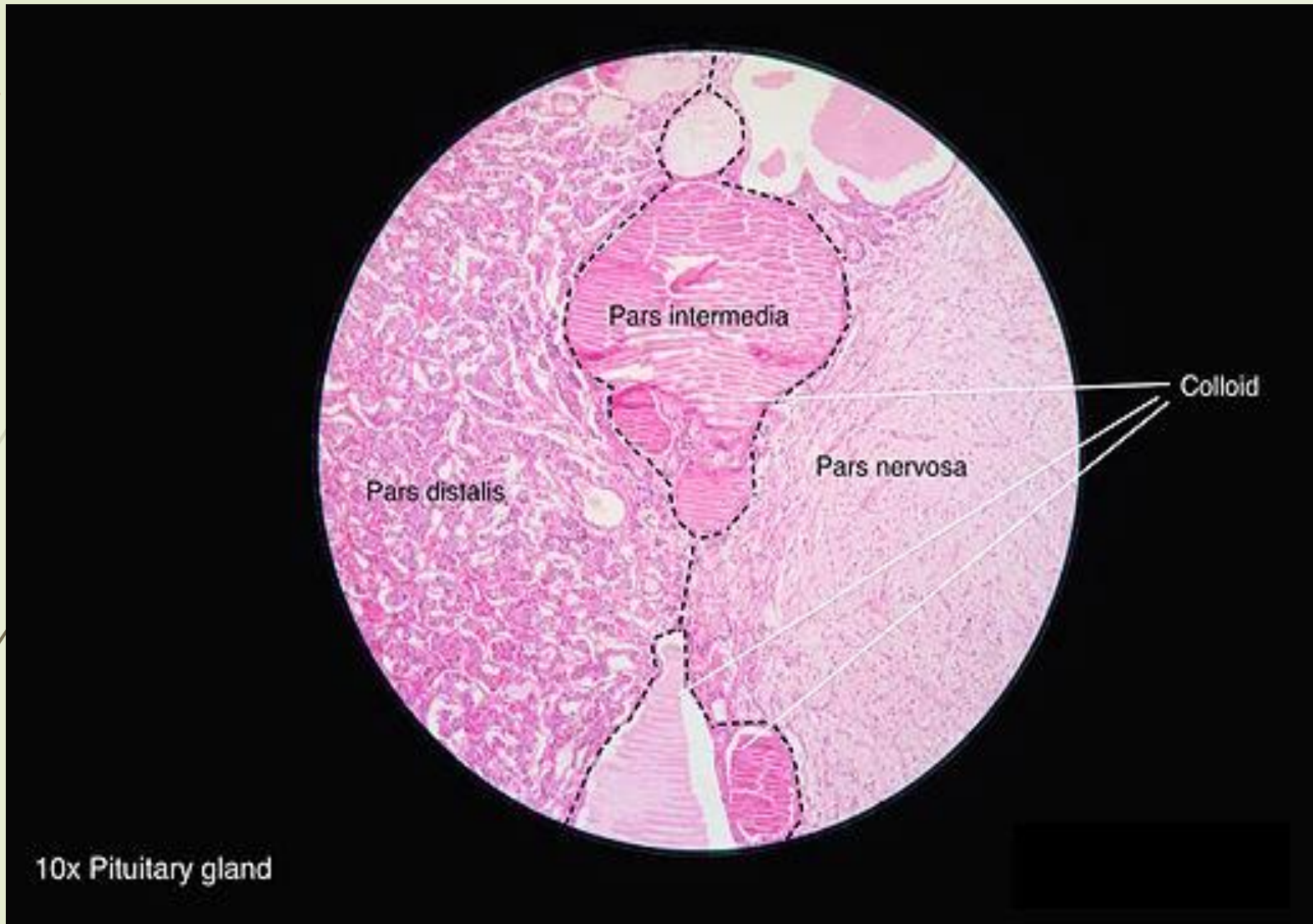
Summary

Close examination of a sectioned pituitary gland reveals two closely apposed, but distinctive tissues called the adenohypophysis (anterior or glandular pituitary) and neurohypophysis (posterior or neural pituitary).

The adenohypophysis is further classified into several regions. The adenohypophysis and neurohypophysis have separate embryological origins.

Microscopic examination of the conventionally-stained adenohypophysis reveals three distinctive cell types called acidophils, basophils and chromophobes. This pattern of staining reflects the chemical character of intracellular hormone-laden granules within the pituitary cells.

The neurohypophysis is an extension of the hypothalamus. It is composed of bundles of axons from hypothalamic neurosecretory neurons intermixed with glial cells.



Histology of pituitary gland

FUNCTIONS OF THE PITUITARY GLAND

Anterior

The anterior pituitary synthesizes and secretes hormones. All releasing hormones (-RH) referred to, can also be referred to as releasing factors (-RF).

Somatotropes :

Human growth hormone (HGH), also referred to as 'growth hormone' (GH), and also as somatotropin, is released under the influence of hypothalamic growth hormone-releasing hormone (GHRH), and is inhibited by hypothalamic somatostatin.



Corticotropes:

Cleaved from the precursor proopiomelanocortin protein, and include adrenocorticotrophic hormone (ACTH), and beta-endorphin, and melanocyte-stimulating hormone are released under the influence of hypothalamic corticotropin-releasing hormone (CRH).

Thyrotropes:

Thyroid-stimulating hormone (TSH), is released under the influence of hypothalamic thyrotropin-releasing hormone (TRH) and is inhibited by somatostatin.



Gonadotropes:

Luteinizing hormone (LH).

**Follicle-stimulating hormone (FSH), both released under influence of
Gonadotropin-releasing Hormone (GnRH)**

Lactotropes:

**Prolactin (PRL), whose release is inconsistently stimulated by
hypothalamic TRH, oxytocin, vasopressin, vasoactive intestinal
peptide, angiotensin II, neuropeptide Y, galanin, substance P,
bombesin-like peptides (gastrin-releasing peptide, neuromedin B
and C), and neurotensin, and inhibited by hypothalamic
dopamine.**

These hormones are released from the anterior pituitary under the influence of the hypothalamus. Hypothalamic hormones are secreted to the anterior lobe by way of a special capillary system, called the hypothalamic-hypophysial portal system.

There is also a non-endocrine cell population called folliculostellate cells.

Intermediate

The intermediate lobe synthesizes and secretes the following important endocrine hormone:

Melanocyte-stimulating hormone (MSH). This is also produced in the anterior lobe.[10] When produced in the intermediate lobe, MSHs are sometimes called "intermedins".

Posterior PITUITARY

The posterior pituitary stores and secretes (but does not synthesize) the following important endocrine hormones:

Magnocellular neurons:

Antidiuretic hormone (ADH, also known as vasopressin and arginine vasopressin AVP), the majority of which is released from the supraoptic nucleus in the hypothalamus.

Oxytocin, most of which is released from the paraventricular nucleus in the hypothalamus. Oxytocin is one of the few hormones to create a positive feedback loop. For example, uterine contractions stimulate the release of oxytocin from the posterior pituitary, which, in turn, increases uterine contractions. This positive feedback loop continues throughout labour.

Hormones

Hormones secreted from the pituitary gland help control the following body processes

Growth (GH)

Blood pressure

Some aspects of pregnancy and childbirth including stimulation of uterine contractions

Breast milk production

Sex organ functions in both sexes

Thyroid gland function

Metabolic conversion of food into energy

Water and osmolarity regulation in the body

Water balance via the control of reabsorption of water by the kidneys

Temperature regulation

Pain relief

Clinical significance

A normal-sized hand (left) and the enlarged hand of someone with acromegaly (right)

Main article: Pituitary disease

Some of the diseases involving the pituitary gland are:

Central diabetes insipidus caused by a deficiency of vasopressin

Gigantism and acromegaly caused by an excess of growth hormone in childhood and adult, respectively

Hypothyroidism caused by a deficiency of thyroid-stimulating hormone

Hyperpituitarism, the increased (hyper) secretion of one or more of the hormones normally produced by the pituitary gland

Hypopituitarism, the decreased (hypo) secretion of one or more of the hormones normally produced by the pituitary gland


Panhypopituitarism a decreased secretion of most of the pituitary hormones

Pituitary tumours


Pituitary adenomas, noncancerous tumors that occur in the pituitary gland

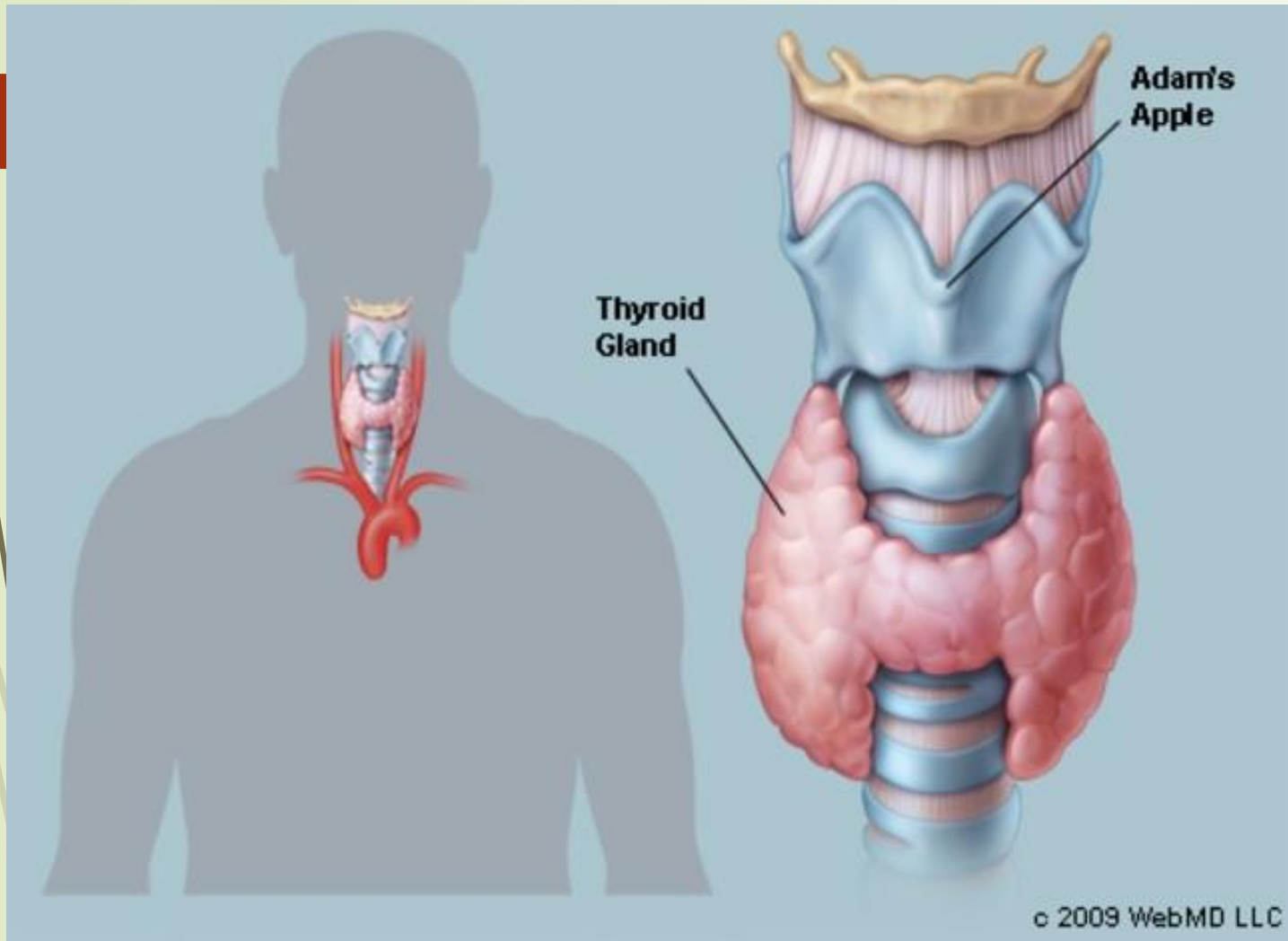
All of the functions of the pituitary gland can be adversely affected by an over- or under-production of associated hormones.

The pituitary gland is important for mediating the stress response, via the hypothalamic–pituitary–adrenal axis (HPA axis) Critically, pituitary gland growth during adolescence can be altered by early life stress such as childhood maltreatment or maternal dysphoric behavior.




**BRIEF ACCOUNT OF
STRUCTURAL FEATURES
HISTOLOGICAL STRUCTURE
AND FUNCTION OF THYROID
GLAND**





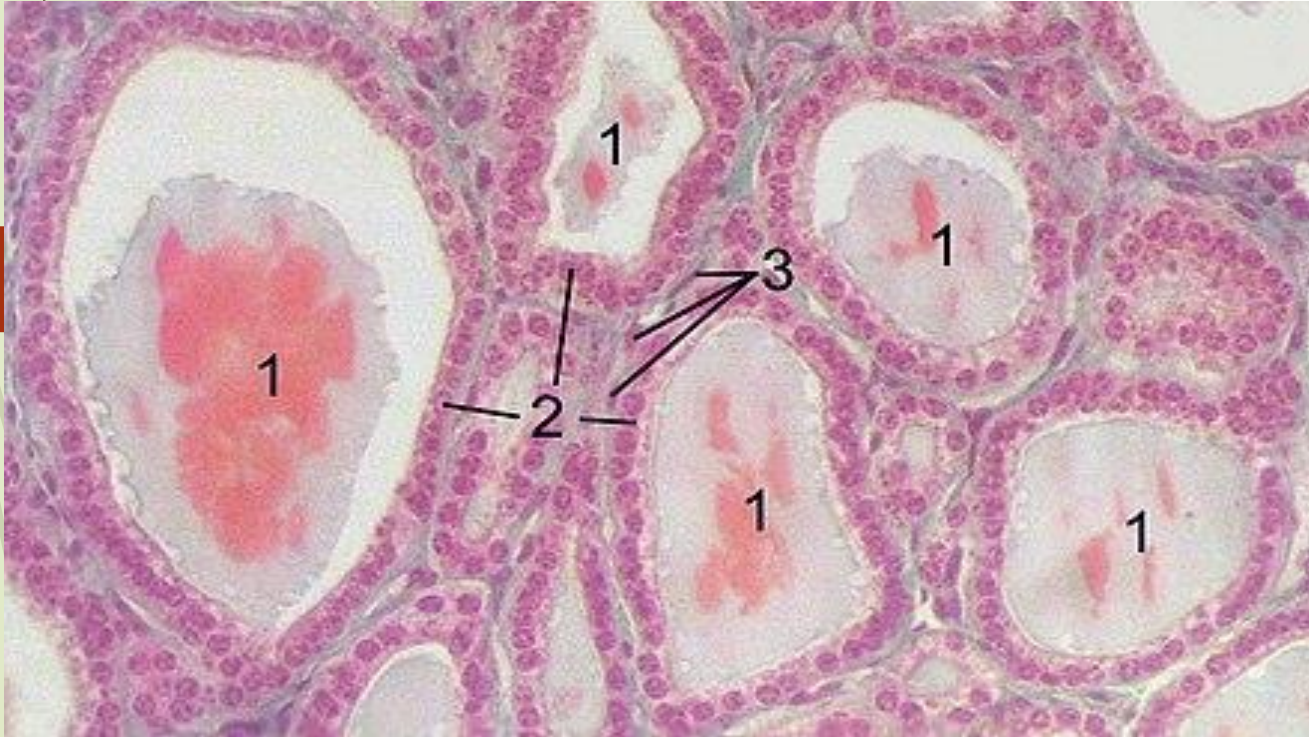
The thyroid is a butterfly-shaped gland that sits low on the front of the neck. Your thyroid lies below your Adam's apple, along the front of the windpipe. The thyroid has two side lobes, connected by a bridge (isthmus) in the middle. When the thyroid is its normal size, you can't feel it.

Brownish-red in color, the thyroid is rich with blood vessels. Nerves important for voice quality also pass through the thyroid.



The thyroid secretes several hormones, collectively called thyroid hormones. The main hormone is thyroxine, also called T₄. Thyroid hormones act throughout the body, influencing metabolism, growth and development, and body temperature. During infancy and childhood, adequate thyroid hormone is crucial for brain development.

STRUCTURE : HISTOLOGY



HISTOLOGY OF

THYROID: Section of

a thyroid gland


under the

microscope.

1 colloid,

2 follicular cells,


3 endothelial cells



At the microscopic level, there are three primary features of the thyroid—**follicles, follicular cells, and parafollicular cells**, first discovered by **Geoffery Websterson in 1664**

Follicles

Thyroid follicles are small spherical groupings of cells 0.02–0.9mm in diameter that play the main role in thyroid function. They consist of a rim that has a rich blood supply, nerve and lymphatic presence, that surrounds a core of colloid that consists mostly of thyroid hormone precursor proteins called thyroglobulin, an iodinated glycoprotein



Follicular cells

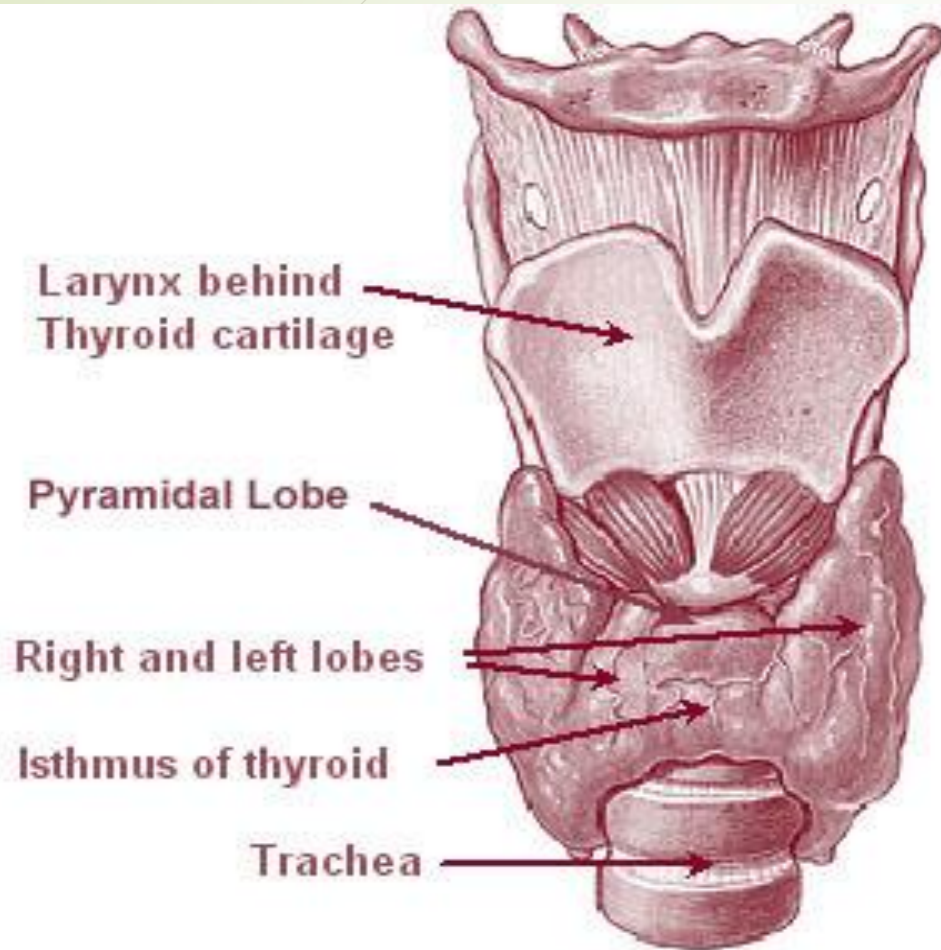
The core of a follicle is surrounded by a single layer of follicular cells. When stimulated by thyroid stimulating hormone (TSH), these secrete the thyroid hormones T3 and T4. They do this by transporting and metabolising the thyroglobulin contained in the colloid.[5]

Follicular cells vary in shape from flat to cuboid to columnar, depending on how active they are.


Parafollicular cells

Scattered among follicular cells and in spaces between the spherical follicles are another type of thyroid cell, parafollicular cells.[5] These cells secrete calcitonin and so are also called C cells

ANATOMICAL STRUCTURE OF THYROID GLAND




The thyroid gland surrounds the cricoid and tracheal cartilages and consists of two lobes. This image shows a variant thyroid with a pyramidal lobe emerging from the middle of the thyroid.



The thyroid gland is a butterfly-shaped organ composed of two lobes, left and right, connected by a narrow tissue band, called an "isthmus" It weighs 25 grams in adults, with each lobe being about 5 cm long, 3 cm wide, and 2 cm thick, and the isthmus about 1.25 cm in height and width The gland is usually larger in women than in men, and increases in size during pregnancy.

The thyroid is near the front of the neck, lying against and around the front of the larynx and trachea. The thyroid cartilage and cricoid cartilage lie just above the gland, below the Adam's apple. The isthmus extends from the second to third rings of the trachea, with the uppermost part of the lobes extending to the thyroid cartilage and the lowermost around the fourth to sixth tracheal rings.




The infrahyoid muscles lie in front of the gland and the sternocleidomastoid muscle to the side. Behind the outer wings of the thyroid lie the two carotid arteries. The trachea, larynx, lower pharynx and esophagus all lie behind the thyroid. In this region, the recurrent laryngeal nerve and the inferior thyroid artery pass next to or in the ligament. Typically, four parathyroid glands, two on each side, lie on each side between the two layers of the thyroid capsule, at the back of the thyroid lobes.

The thyroid gland is covered by a thin fibrous capsule, which has an inner and an outer layer. The inner layer extrudes into the gland and forms the septae that divide the thyroid tissue into microscopic lobules.

The outer layer is continuous with the pretracheal fascia, attaching the gland to the cricoid and thyroid cartilage via a thickening of the fascia to form the posterior suspensory ligament of thyroid gland, also known as Berry's ligament. This causes the thyroid to move up and down with the movement of these cartilages when swallowing occurs.

Blood, lymph and nerve supply

The thyroid is supplied with arterial blood from the superior thyroid artery, a branch of the external carotid artery, and the inferior thyroid artery, a branch of the thyrocervical trunk, and sometimes by an anatomical variant the thyroid ima artery, which has a variable origin. The superior thyroid artery splits into anterior and posterior branches supplying the thyroid, and the inferior thyroid artery splits into superior and inferior branches



The superior and inferior thyroid arteries join together behind the outer part of the thyroid lobes. The venous blood is drained via superior and middle thyroid veins, which drain to the internal jugular vein, and via the inferior thyroid veins. The inferior thyroid veins originate in a network of veins and drain into the left and right brachiocephalic veins. Both arteries and veins form a plexus between the two layers of the capsule of the thyroid gland.

Lymphatic drainage frequently passes the prelaryngeal lymph nodes (located just above the isthmus), and the pretracheal and paratracheal lymph nodes. The gland receives sympathetic nerve supply from the superior, middle and inferior cervical ganglion of the sympathetic trunk. The gland receives parasympathetic nerve supply from the superior laryngeal nerve and the recurrent laryngeal nerve.

Function:

Diagram explaining the relationship between the thyroid hormones T3 and T4, thyroid stimulating hormone (TSH), and thyrotropin releasing hormone (TRH)

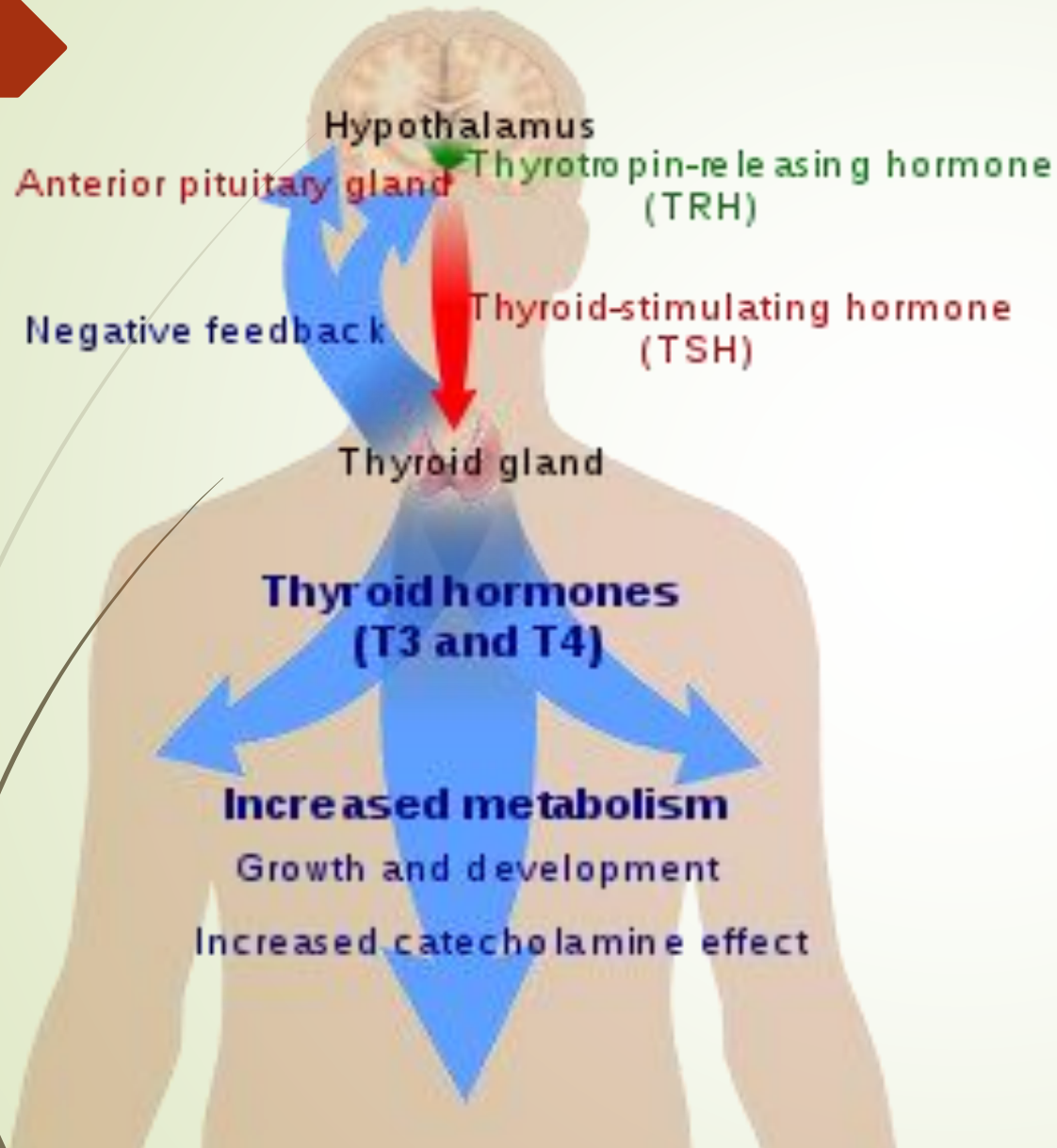
The thyroid hormones T3 and T4 have a number of metabolic, cardiovascular and developmental effects on the body. The production is stimulated by release of thyroid stimulating hormone (TSH), which in turn depends on release of thyrotropin releasing hormone (TRH). Every downstream hormone has negative feedback and decreases the level of the hormone that stimulates its release.

Thyroid hormones


Thyroid hormones

The primary function of the thyroid is the production of the iodine-containing thyroid hormones, triiodothyronine (T3) and thyroxine (T4) and the peptide hormone calcitonin. The thyroid hormones are created from iodine and tyrosine. T3 is so named because it contains three atoms of iodine per molecule and T4 contains four atoms of iodine per molecule. The thyroid hormones have a wide range of effects on the human body. These include:

Thyroid system




The thyroid hormones T3 and T4 have a number of metabolic, cardiovascular and developmental effects on the body. The production is stimulated by release of thyroid stimulating hormone (TSH), which in turn depends on release of thyrotropin releasing hormone (TRH). Every downstream hormone has negative feedback and decreases the level of the hormone that stimulates its release.



Metabolic. The thyroid hormones increase the basal metabolic rate and have effects on almost all body tissues. Appetite, the absorption of substances, and gut motility are all influenced by thyroid hormones. They increase the absorption in the gut, generation, uptake by cells, and breakdown of glucose. They stimulate the breakdown of fats, and increase the number of free fatty acids. Despite increasing free fatty acids, thyroid hormones decrease cholesterol levels, perhaps by increasing the rate of secretion of cholesterol in bile


Cardiovascular. The hormones increase the rate and strength of the heartbeat. They increase the rate of breathing, intake and consumption of oxygen, and increase the activity of mitochondria. Combined, these factors increase blood flow and the body's temperature.

Developmental. Thyroid hormones are important for normal development. They increase the growth rate of young people, and cells of the developing brain are a major target for the thyroid hormones T3 and T4. Thyroid hormones play a particularly crucial role in brain maturation during fetal development and first few years of postnatal life




The thyroid hormones also play a role in maintaining normal sexual function, sleep, and thought patterns. Increased levels are associated with increased speed of thought generation but decreased focus. Sexual function, including libido and the maintenance of a normal menstrual cycle, are influenced by thyroid hormones.


After secretion, only a very small proportion of the thyroid hormones travel freely in the blood. Most are bound to thyroxine-binding globulin (about 70%), transthyretin (10%), and albumin (15%). Only the 0.03% of T4 and 0.3% of T3 traveling freely have hormonal activity. In addition, up to 85% of the T3 in blood is produced following conversion from T4 by iodothyronine deiodinases in organs around the body.



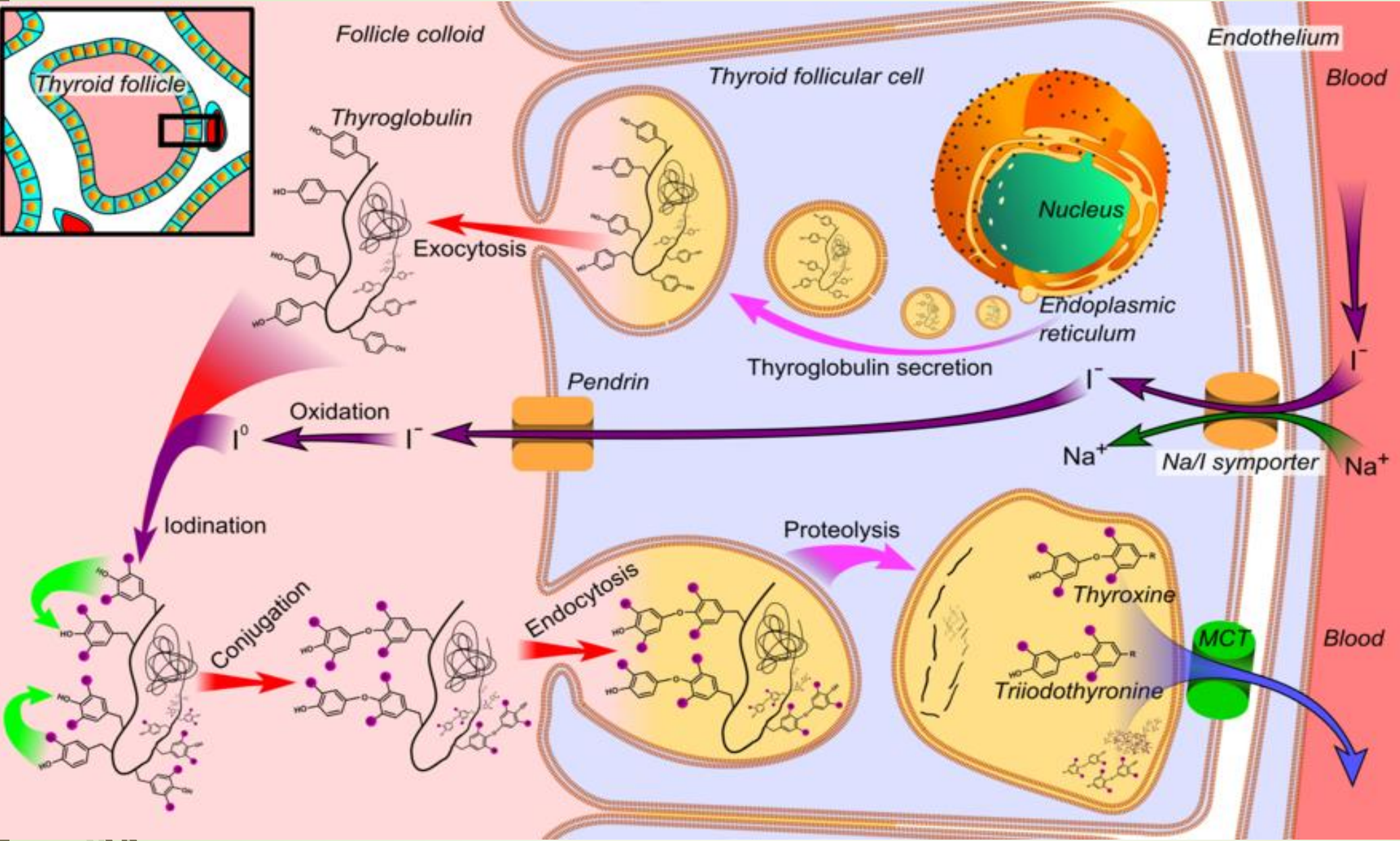
Thyroid hormones act by crossing the cell membrane and binding to intracellular nuclear thyroid hormone receptors TR- α 1, TR- α 2, TR- β 1 and TR- β 2, which bind with hormone response elements and transcription factors to modulate DNA transcription. In addition to these actions on DNA, the thyroid hormones also act within the cell membrane or within cytoplasm via reactions with enzymes, including calcium ATPase, adenylyl cyclase, and glucose transporters



HORMONE PRODUCTION: The thyroid hormones are created from thyroglobulin. This is a protein within the colloid in the follicular lumen that is originally created within the rough endoplasmic reticulum of follicular cells and then transported into the follicular lumen. Thyroglobulin contains 123 units of tyrosine, which reacts with iodine within the follicular lumen




Synthesis of the thyroid hormones, as seen on an individual thyroid follicular cell




Thyroglobulin is synthesized in the rough endoplasmic reticulum and follows the secretory pathway to enter the colloid in the lumen of the thyroid follicle by exocytosis.

- Meanwhile, a sodium-iodide (Na/I) symporter pumps iodide (I^-) actively into the cell, which previously has crossed the endothelium by largely unknown mechanisms.
- This iodide enters the follicular lumen from the cytoplasm by the transporter pendrin, in a purportedly passive manner.
- In the colloid, iodide (I^-) is oxidized to iodine by an enzyme called thyroid peroxidase.
- Iodine (I_0) is very reactive and iodinates the thyroglobulin at tyrosyl residues in its protein chain (in total containing approximately 120 tyrosyl residues).
- In conjugation, adjacent tyrosyl residues are paired together.
- The entire complex re-enters the follicular cell by endocytosis.
- Proteolysis by various proteases liberates thyroxine and triiodothyronine molecules, which enters the blood by largely unknown mechanisms



Iodine is essential for the production of the thyroid hormones. Iodine (I_0) travels in the blood as iodide (I^-), which is taken up into the follicular cells by a sodium-iodide symporter. This is an ion channel on the cell membrane which in the same action transports two sodium ions and an iodide ion into the cell. Iodide then travels from within the cell into the lumen, through the action of pendrin, an iodide-chloride antiporter. In the follicular lumen, the iodide is then oxidized to iodine. This makes it more reactive, and the iodine is attached to the active tyrosine units in thyroglobulin by the enzyme thyroid peroxidase. This forms the precursors of thyroid hormones monoiodotyrosine (MIT), and diiodotyrosine (DIT)



When the follicular cells are stimulated by thyroid-stimulating hormone, the follicular cells reabsorb thyroglobulin from the follicular lumen. The iodinated tyrosines are cleaved, forming the thyroid hormones T₄, T₃, DIT, MIT, and traces of reverse triiodothyronine. T₃ and T₄ are released into the blood. The hormones secreted from the gland are about 80–90% T₄ and about 10–20% T₃. Deiodinase enzymes in peripheral tissues remove the iodine from MIT and DIT and convert T₄ to T₃ and RT₃. This is a major source of both RT₃ (95%) and T₃ (87%) in peripheral tissues.

Regulation

The production of thyroxine and triiodothyronine is primarily regulated by thyroid-stimulating hormone (TSH), released by the anterior pituitary gland. TSH release in turn is stimulated by thyrotropin releasing hormone (TRH), released in a pulsatile manner from the hypothalamus. The thyroid hormones provide negative feedback to the thyrotropes TSH and TRH: when the thyroid hormones are high, TSH production is suppressed. This negative feedback also occurs when levels of TSH are high, causing TRH production to be suppressed.

TRH is secreted at an increased rate in situations such as cold exposure in order to stimulate thermogenesis. In addition to being suppressed by the presence of thyroid hormones, TSH production is blunted by dopamine, somatostatin, and glucocorticoids

Calcitonin

Calcitonin

The thyroid gland also produces the hormone calcitonin, which helps regulate blood calcium levels. Parafollicular cells produce calcitonin in response to high blood calcium. Calcitonin decreases the release of calcium from bone, by decreasing the activity of osteoclasts, cells which break down bone. Bone is constantly reabsorbed by osteoclasts and created by osteoblasts, so calcitonin effectively stimulates movement of calcium into bone. The effects of calcitonin are opposite those of the parathyroid hormone (PTH) produced in the parathyroid glands. However, calcitonin seems far less essential than PTH, since calcium metabolism remains clinically normal after removal of the thyroid (thyroidectomy), but not the parathyroid glands.



Gene and protein expression

Further information: Bioinformatics § Gene and protein expression

About 20,000 protein coding genes are expressed in human cells:

70% of these genes are expressed in thyroid cells. Two-hundred fifty

of these genes are more specifically expressed in the thyroid, and

about 20 genes are highly thyroid specific. In the follicular cells, the

proteins synthesized by these genes direct thyroid hormone

synthesis - thyroglobulin, TPO, and IYD; while in the parafollicular c-

cells, they direct calcitonin synthesis - CALCA, and CALCB.

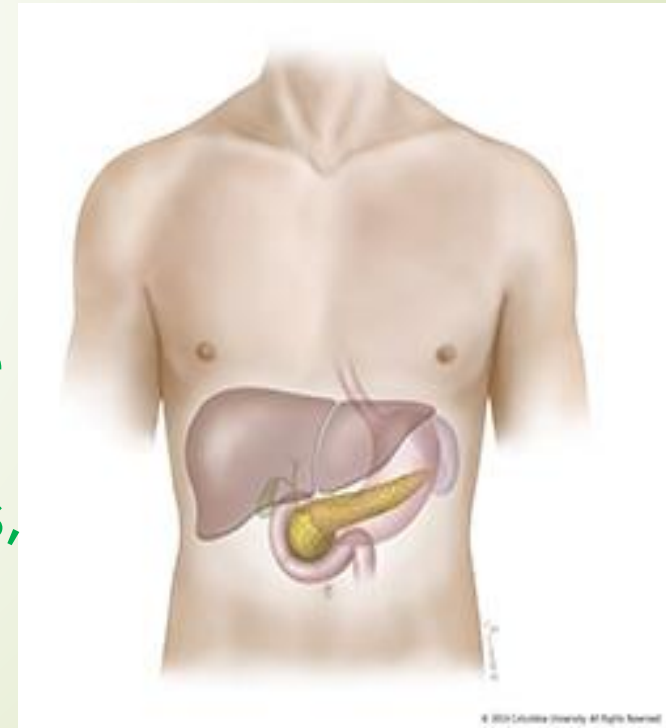
Thyroid cancer

The most common neoplasm affecting the thyroid gland is a benign adenoma, usually presenting as a painless mass in the neck. Malignant thyroid cancers are most often carcinomas, although cancer can occur in any tissue that the thyroid consists of, including cancer of C-cells and lymphomas. Cancers from other sites also rarely lodge in the thyroid. Radiation of the head and neck presents a risk factor for thyroid cancer, and cancer is more common in women than men, occurring at a rate of about

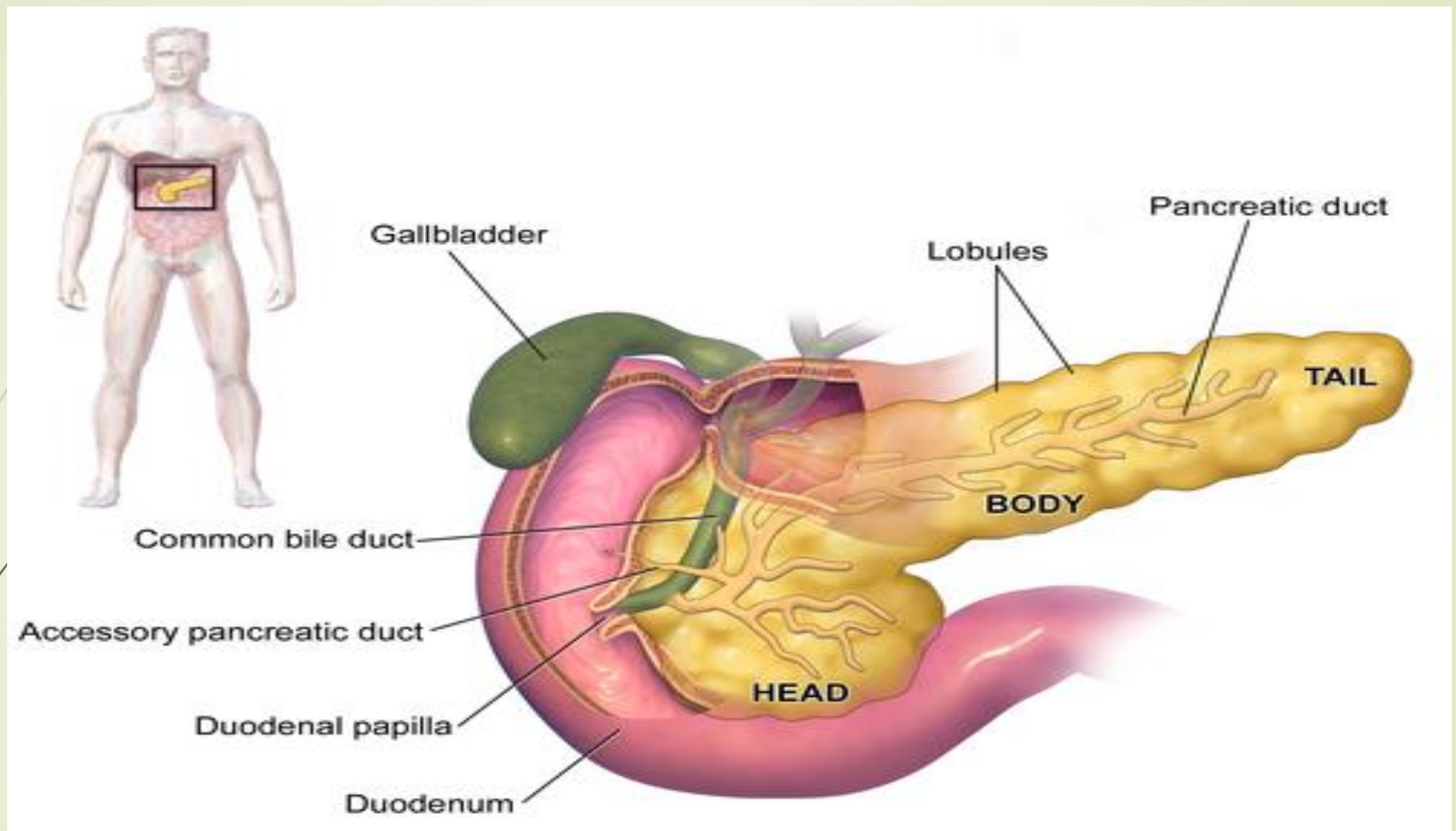
BRIEF ACCOUNT OF STRUCTURAL FEATURES

HISTOLOGICAL STRUCTURE AND FUNCTION OF PANCREAS

The pancreas is a glandular organ in the upper abdomen, but really it serves as two glands in one: a digestive exocrine gland and a hormone-producing endocrine gland. Functioning as an exocrine gland, the pancreas excretes enzymes to break down the proteins, lipids, carbohydrates, and nucleic acids in food



The pancreas is an organ of the digestive system and endocrine system of vertebrates. In humans, it is located in the abdomen behind the stomach and functions as a gland. The pancreas has both an endocrine and a digestive exocrine function. As an endocrine gland, it functions mostly to regulate blood sugar levels, secreting the hormones insulin, glucagon, somatostatin, and pancreatic polypeptide. As a part of the digestive system, it functions as an exocrine gland secreting pancreatic juice into the duodenum through the pancreatic duct. This juice contains bicarbonate, which neutralizes acid entering the duodenum from the stomach; and digestive enzymes, which break down carbohydrates, proteins, and fats in food entering the duodenum from the stomach.




ANATOMY OF PANCREAS

STRUCTURE

The pancreas is an organ that in humans lies in the abdomen, stretching from behind the stomach to the left upper abdomen near the spleen. In adults, it is about 12–15 centimeters (4.7–5.9 in) long, and salmon-coloured in appearance


Anatomically, the pancreas is divided into a head, neck, body, and tail. The pancreas stretches from the inner curvature of the duodenum, where the head surrounds two blood vessels: the superior mesenteric artery, and vein. The longest part of the pancreas, the body, stretches across behind the stomach, and the tail of the pancreas ends adjacent to the spleen

A decorative red arrow points to the right at the top left. Several thin, curved lines in shades of green and grey sweep across the left side of the slide.

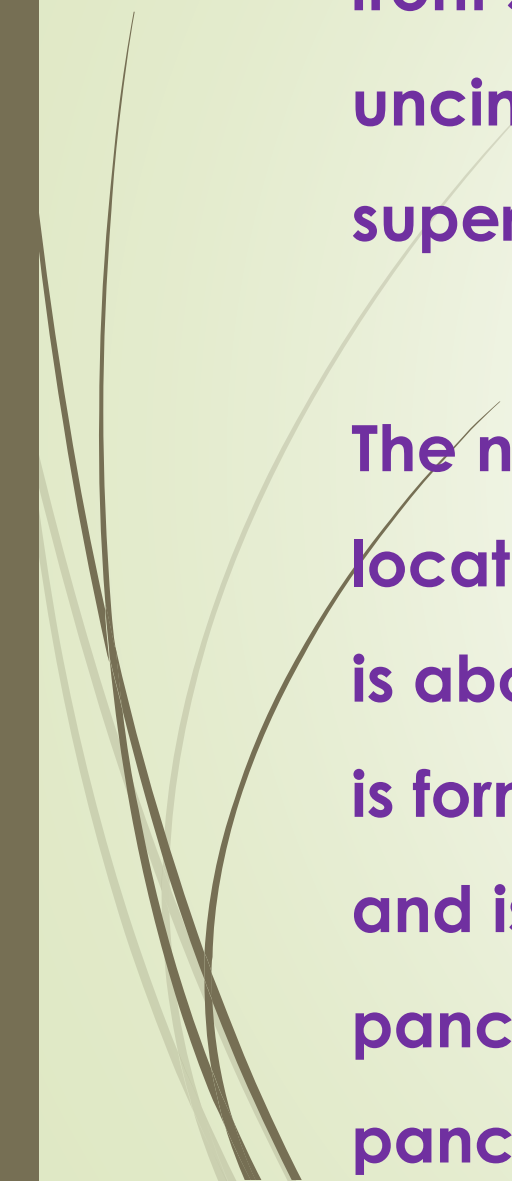
Two ducts, the main pancreatic duct and a smaller accessory pancreatic duct, run through the body of the pancreas, joining with the common bile duct near a small ballooning called the ampulla of Vater. Surrounded by a muscle, the sphincter of Oddi, this opens into the descending part of the duodenum.

Parts

The head of the pancreas sits within the curvature of the duodenum, and wraps around the superior mesenteric artery and vein. To the right sits the descending part of the duodenum, and between these travel the superior and inferior pancreaticoduodenal arteries.



Behind rests the inferior vena cava, and the common bile duct. In front sits the peritoneal membrane and the transverse colon. A small uncinata process emerges from below the head, situated behind the superior mesenteric vein and sometimes artery.

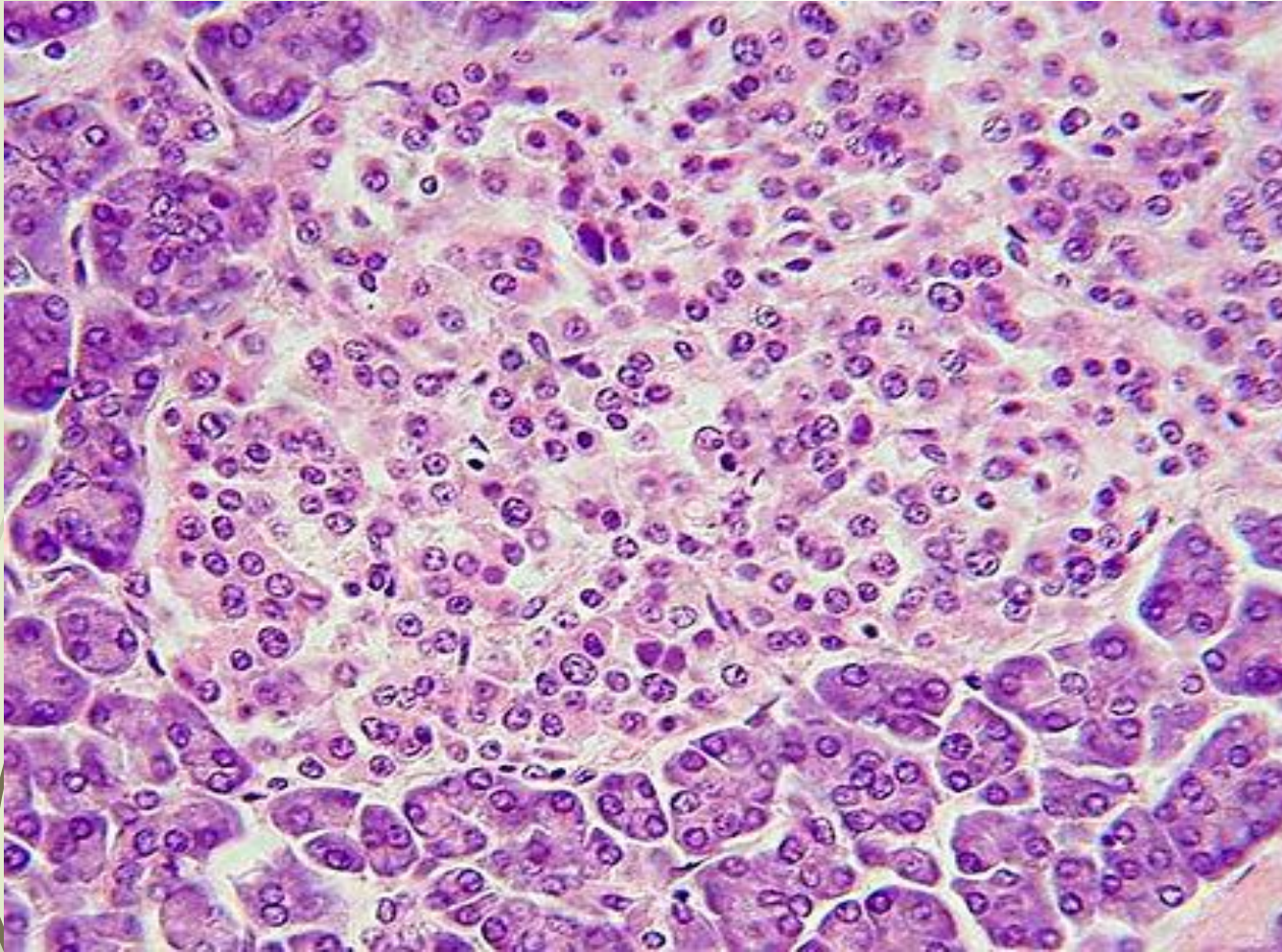


The neck of the pancreas separates the head of the pancreas, located in the curvature of the duodenum, from the body. The neck is about 2 cm (0.79 in) wide, and sits in front of where the portal vein is formed. The neck lies mostly behind the pylorus of the stomach, and is covered with peritoneum. The anterior superior pancreaticoduodenal artery travels in front of the neck of the pancreas.

The body is the largest part of the pancreas, and mostly lies behind the stomach, tapering along its length. The peritoneum sits on top of the body of the pancreas, and the transverse colon in front of the peritoneum. Behind the pancreas are several blood vessels, including the aorta, the splenic vein, and the left renal vein, as well as the beginning of the superior mesenteric artery. Below the body of the pancreas sits some of the small intestine, specifically the last part of the duodenum and the jejunum to which it connects, as well as the suspensory ligament of the duodenum which falls between these two. In front of the pancreas sits the transverse colon.

The pancreas narrows towards the tail, which sits near to the spleen. It is usually between 1.3–3.5 cm (0.51–1.38 in) long, and sits between the layers of the ligament between the spleen and the left kidney. The splenic artery and vein, which also passes behind the body of the pancreas, pass behind the tail of the pancreas. [

HISTOLOGICAL STRUCTURE OF PANCREAS



This image shows a pancreatic islet when pancreatic tissue is stained and viewed under a microscope. Parts of the digestive ("exocrine") pancreas can be seen around the islet, more darkly. These contain hazy dark purple granules of inactive digestive enzymes (zymogens).

The pancreas contains tissue with an endocrine and exocrine role, and this division is also visible when the pancreas is viewed under a microscope.

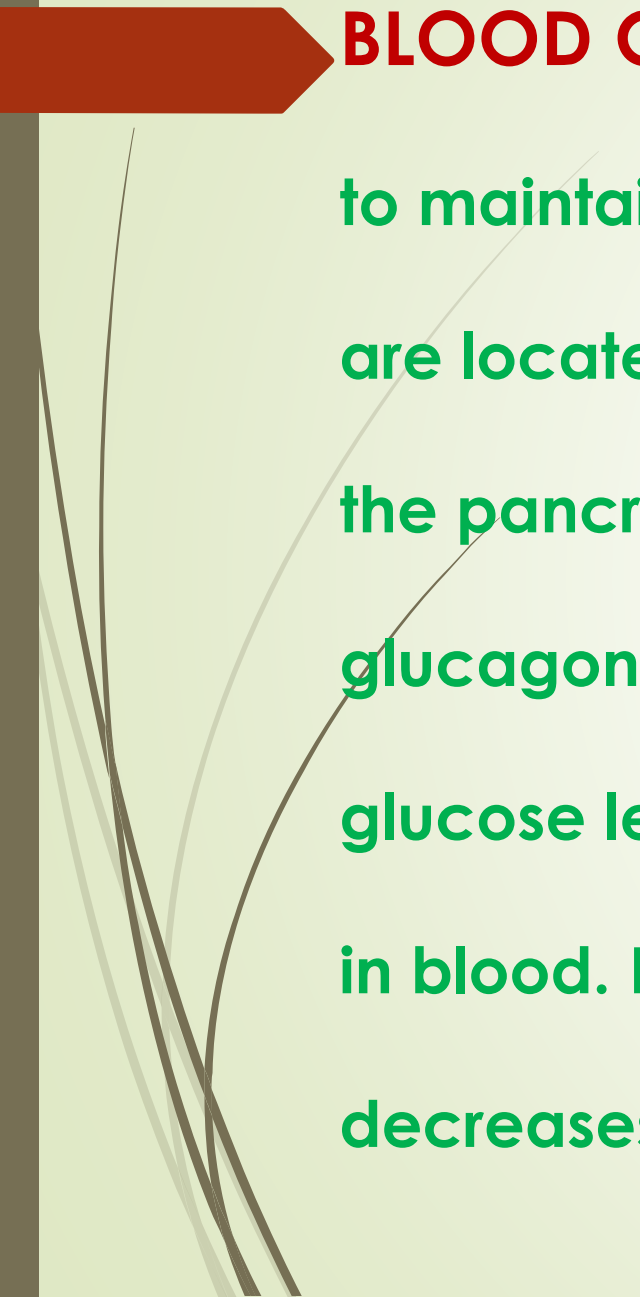
The majority of pancreatic tissue has a digestive role. The cells with this role form clusters (Latin: acini) around small ducts, and are arranged in lobes that have thin fibrous walls. The cells of each acinus secrete inactive digestive enzymes called zymogens into the small intercalated ducts which they surround. In each acinus, the cells are pyramid-shaped and situated around the intercalated ducts, with the nuclei resting on the basement membrane, a large endoplasmic reticulum, and a number of zymogen granules visible within the cytoplasm. The intercalated ducts drain into larger intralobular ducts within the lobule, and finally interlobular ducts. The ducts are lined by a single layer of column-shaped cells

There is more than one layer of cells as the diameter of the ducts increases.


The tissues with an endocrine role within the pancreas exist as clusters of cells called pancreatic islets (also called islets of Langerhans) that are distributed throughout the pancreas. Pancreatic islets contain alpha cells, beta cells, and delta cells, each of which releases a different hormone. These cells have characteristic positions, with alpha cells (secreting glucagon) tending to be situated around the periphery of the islet, and beta cells (secreting insulin) more numerous and found throughout the islet. Enterochromaffin cells are also scattered throughout the islets. Islets are composed of up to 3,000 secretory cells, and contain several small arterioles to receive blood, and venules that allow the hormones secreted by the cells to enter the systemic circulation.

Function


The pancreas is involved in blood sugar control and metabolism within the body, and also in the secretion of substances (collectively pancreatic juice) that help digestion. These are divided into an "endocrine" role, relating to the secretion of insulin and other substances within pancreatic islets that help control blood sugar levels and metabolism within the body, and an "exocrine" role, relating to the secretion of enzymes involved in digesting substances in the digestive tract

A red arrow points from the left edge of the slide towards the text. Several thin, curved lines in shades of brown and grey originate from the left side and sweep across the slide, partially overlapping the text.

BLOOD GLUCOSE REGULATION: Cells within the pancreas help to maintain blood glucose levels (homeostasis). The cells that do this are located within the pancreatic islets that are present throughout the pancreas. When blood glucose levels are low, alpha cells secrete glucagon, which increases blood glucose levels. When blood glucose levels are high beta cells secrete insulin to decrease glucose in blood. Delta cells in the islet also secrete somatostatin which decreases the release of insulin and glucagon.



Glucagon acts to increase glucose levels by promoting the creation of glucose and the breakdown of glycogen to glucose in the liver. It also decreases the uptake of glucose in fat and muscle. Glucagon release is stimulated by low blood glucose or insulin levels, and during exercise. Insulin acts to decrease blood glucose levels by facilitating uptake by cells (particularly skeletal muscle), and promoting its use in the creation of proteins, fats and carbohydrates. Insulin is initially created as a precursor form called preproinsulin. This is converted to proinsulin and cleaved by C-peptide to insulin which is then stored in granules in beta cells. Glucose is taken into the beta cells and degraded. The end effect of this is to cause depolarisation of the cell membrane which stimulates the release of the insulin.



The main factor influencing the secretion of insulin and glucagon are the levels of glucose in blood plasma. Low blood sugar stimulates glucagon release, and high blood sugar stimulates insulin release.

DIGESTION: The pancreas plays a vital role in the digestive system. It does this by secreting a fluid that contains digestive enzymes into the duodenum, the first part of the small intestine that receives food from the stomach. These enzymes help to break down carbohydrates, proteins and lipids (fats). This role is called the "exocrine" role of the pancreas. The cells that do this are arranged in clusters called acini. Secretions into the middle of the acinus accumulate in intralobular ducts, which drain to the main pancreatic duct, which drains directly into the duodenum. About 1.5 - 3 liters of fluid are secreted in this manner every day

The cells in each acinus are filled with granules containing the digestive enzymes. These are secreted in an inactive form termed zymogens or proenzymes. When released into the duodenum, they are activated by the enzyme enterokinase present in the lining of the duodenum. The proenzymes are cleaved, creating a cascade of activating enzymes.

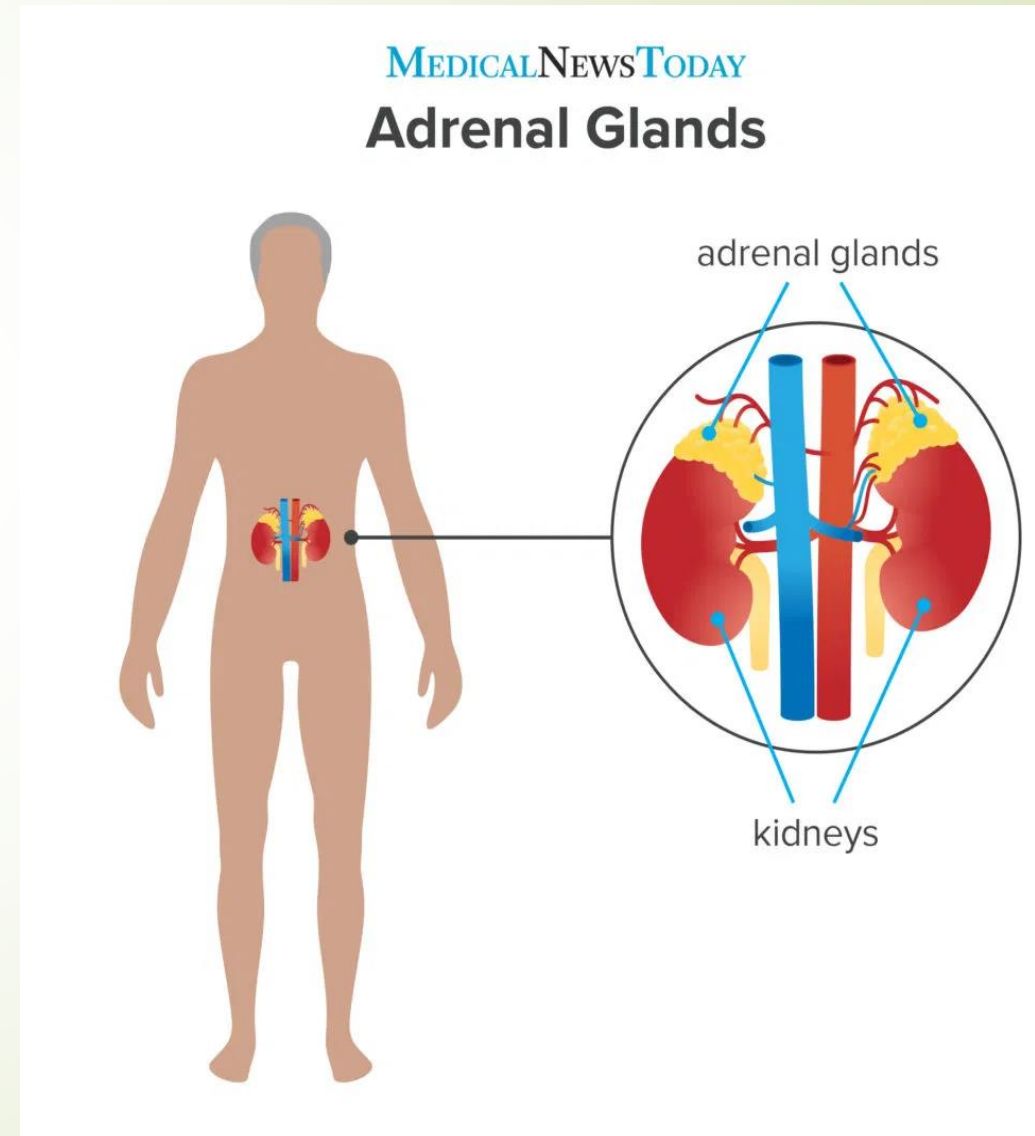
Enzymes that break down proteins begin with activation of trypsinogen to trypsin. The free trypsin then cleaves the rest of the trypsinogen, as well as chymotrypsinogen to its active form chymotrypsin.

Enzymes secreted involved in the digestion of fats include lipase, phospholipase A2, lysophospholipase, and cholesterol esterase.

Enzymes that breakdown starch and other carbohydrates include amylase

BRIEF ACCOUNT OF STRUCTURAL FEATURES HISTOLOGICAL STRUCTURE AND FUNCTION OF ADRENAL GLAND

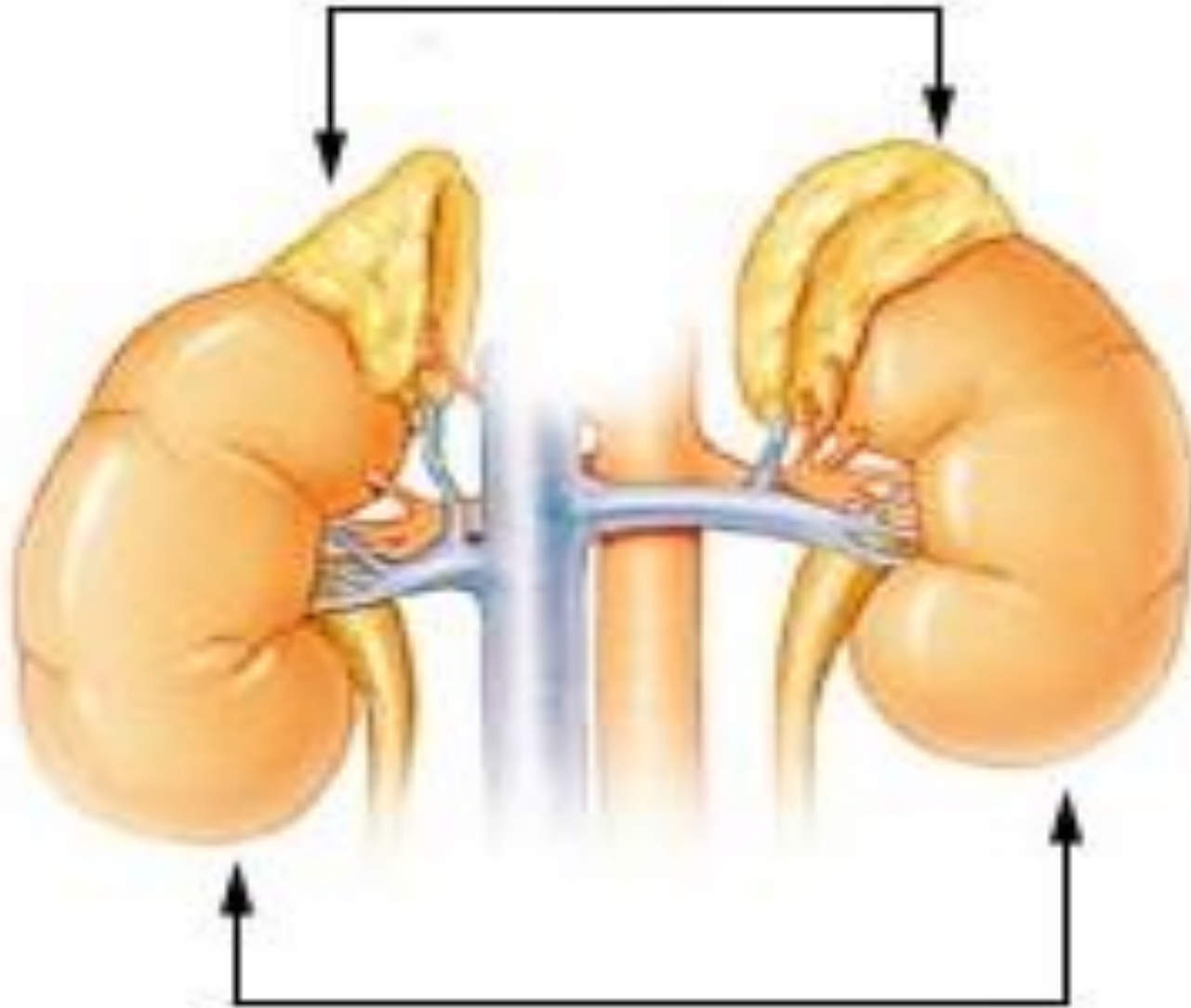
The adrenal glands (also known as suprarenal glands) are endocrine glands that produce a variety of hormones including adrenaline and the steroids aldosterone and cortisol. They are found above the kidneys. Each gland has an outer cortex which produces steroid hormones and an inner medulla.



The adrenal cortex itself is divided into three zones: the zona glomerulosa, the zona fasciculata and the zona reticularis.

The adrenal cortex produces three main types of steroid hormones: mineralocorticoids, glucocorticoids, and androgens. Mineralocorticoids (such as aldosterone) produced in the zona glomerulosa help in the regulation of blood pressure and electrolyte balance. The glucocorticoids cortisol and cortisone are synthesized in the zona fasciculata; their functions include the regulation of metabolism and immune system suppression. The innermost layer of the cortex, the zona reticularis, produces androgens that are converted to fully functional sex hormones in the gonads and other target organs. The production of steroid hormones is called steroidogenesis, and involves a number of reactions and processes that take place in cortical cells. The medulla produces the catecholamines, which function to produce a rapid response throughout the body in stress situations.

Adrenal gland



Kidney

The adrenal glands lie above the kidneys.

Structure

The adrenal glands are located on both sides of the body in the retroperitoneum, above and slightly medial to the kidneys. In humans, the right adrenal gland is pyramidal in shape, whereas the left is semilunar or crescent shaped and somewhat larger. The adrenal glands measure approximately 3 cm in width, 5.0 cm in length, and up to 1.0 cm in thickness. Their combined weight in an adult human ranges from 7 to 10 grams. The glands are yellowish in colour.

The adrenal glands are surrounded by a fatty capsule and lie within the renal fascia, which also surrounds the kidneys. A weak septum (wall) of connective tissue separates the glands from the kidneys. The adrenal glands are directly below the diaphragm, and are attached to the crura of the diaphragm by the renal fascia.

Each adrenal gland has two distinct parts, each with a unique function, the outer adrenal cortex and the inner medulla, both of which produce hormones

Adrenal cortex

Section of human adrenal gland under the microscope, showing its different layers.

From the surface to the center: zona glomerulosa, zona fasciculata, zona reticularis, medulla. In the medulla, the central adrenomedullary vein is visible.

The adrenal cortex is the outermost layer of the adrenal gland. Within the cortex are three layers, called "zones". When viewed under a microscope each layer has a distinct appearance, and each has a different function. The adrenal cortex is devoted to production of hormones, namely aldosterone, cortisol, and androgens.

Zona glomerulosa

The outermost zone of the adrenal cortex is the zona glomerulosa. It lies immediately under the fibrous capsule of the gland. Cells in this layer form oval groups, separated by thin strands of connective tissue from the fibrous capsule of the gland and carry wide capillaries.

This layer is the main site for production of aldosterone, a mineralocorticoid, by **the action** of the enzyme aldosterone synthase. Aldosterone plays an important role in the long-term regulation of blood pressure.

Fascinated area


The zona fasciculata is situated between the zona glomerulosa and zona reticularis. Cells in this layer are responsible for producing glucocorticoids such as cortisol. It is the largest of the three layers, accounting for nearly 80% of the volume of the cortex. In the zona fasciculata, cells are arranged in columns radially oriented towards the medulla. Cells contain numerous lipid droplets, abundant mitochondria and a complex smooth endoplasmic reticulum.

Zona reticularis

The innermost cortical layer, the zona reticularis, lies directly adjacent to the medulla. It produces androgens, mainly dehydroepiandrosterone (DHEA), DHEA sulfate (DHEA-S), and androstenedione (the precursor to testosterone) in humans. Its small cells form irregular cords and clusters, separated by capillaries and connective tissue. The cells contain relatively small quantities of cytoplasm and lipid droplets, and sometimes display brown lipofuscin pigment.

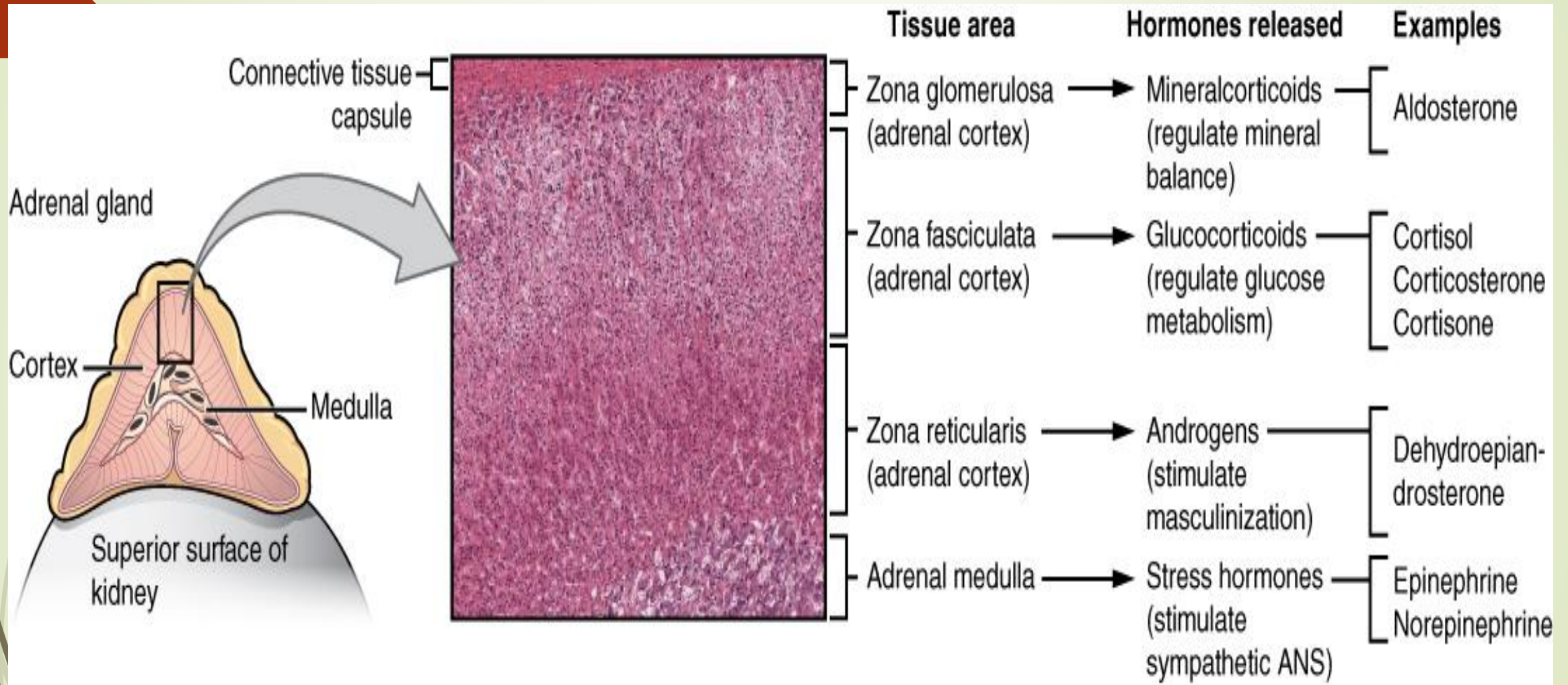
Adrenal medulla

The adrenal medulla is at the centre of each adrenal gland, and is surrounded by the adrenal cortex. The chromaffin cells of the medulla are the body's main source of the catecholamines adrenaline and noradrenaline, released by the medulla. Approximately 20% noradrenaline (norepinephrine) and 80% adrenaline (epinephrine) are secreted here.



The adrenal medulla is driven by the sympathetic nervous system via preganglionic fibers originating in the thoracic spinal cord, from vertebrae. Because it is innervated by preganglionic nerve fibers, the adrenal medulla can be considered as a specialized sympathetic ganglion. Unlike other sympathetic ganglia, however, the adrenal medulla lacks distinct synapses and releases its secretions directly into the blood.

FUNCTION OF ADRENAL GLAND



Different hormones are produced in different zones of the cortex and medulla of the gland.

The adrenal gland secretes a number of different hormones which are metabolised by enzymes either within the gland or in other parts of the body. These hormones are involved in a number of essential biological functions.

Corticosteroids

Corticosteroids are a group of steroid hormones produced from the cortex of the adrenal gland, from which they are named. Corticosteroids are named according to their actions:

Mineralocorticoids such as aldosterone regulate salt ("mineral") balance and blood volume.

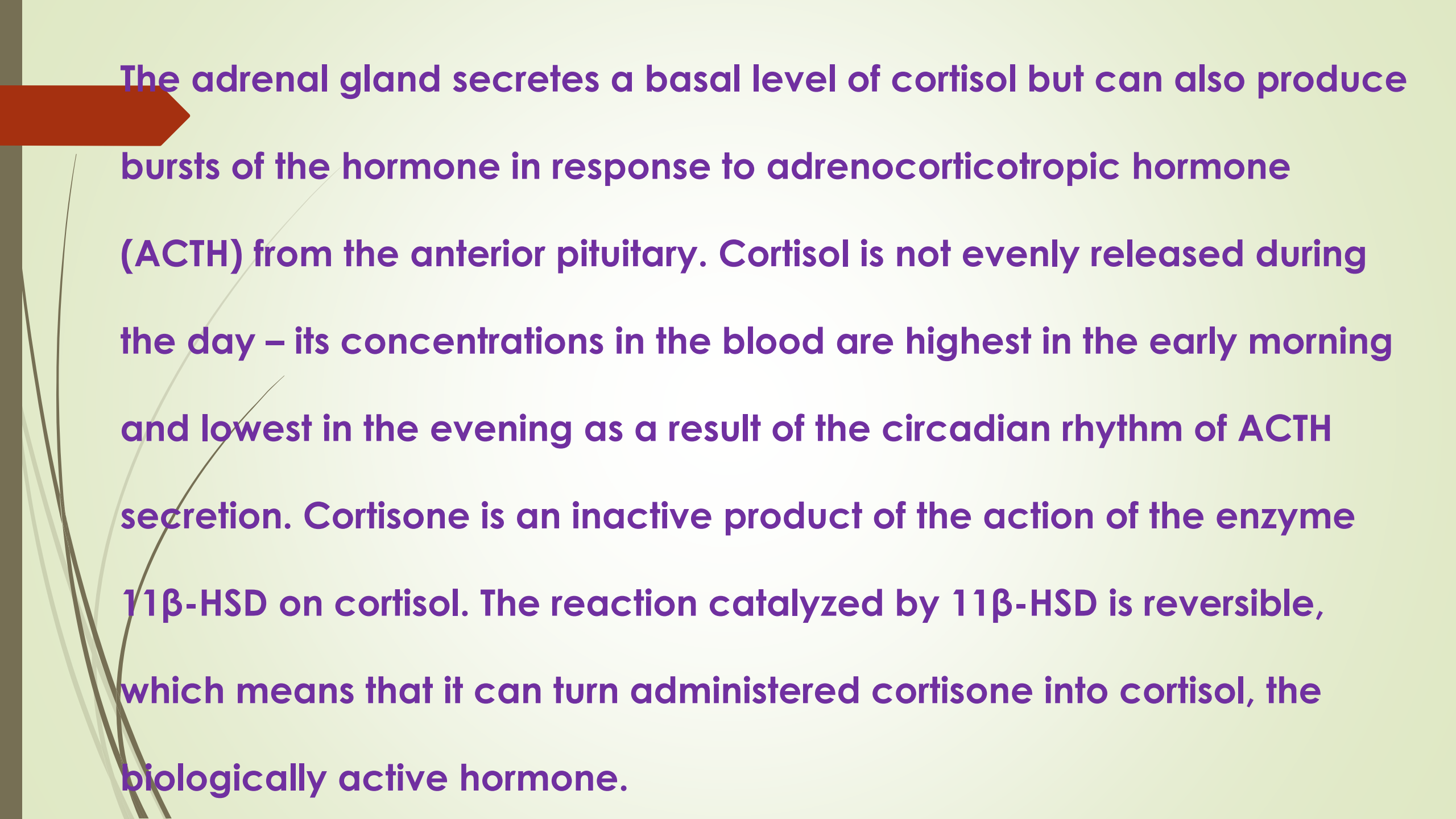
Glucocorticoids such as cortisol influence metabolism rates of proteins, fats and sugars ("glucose")

Mineralocorticoids

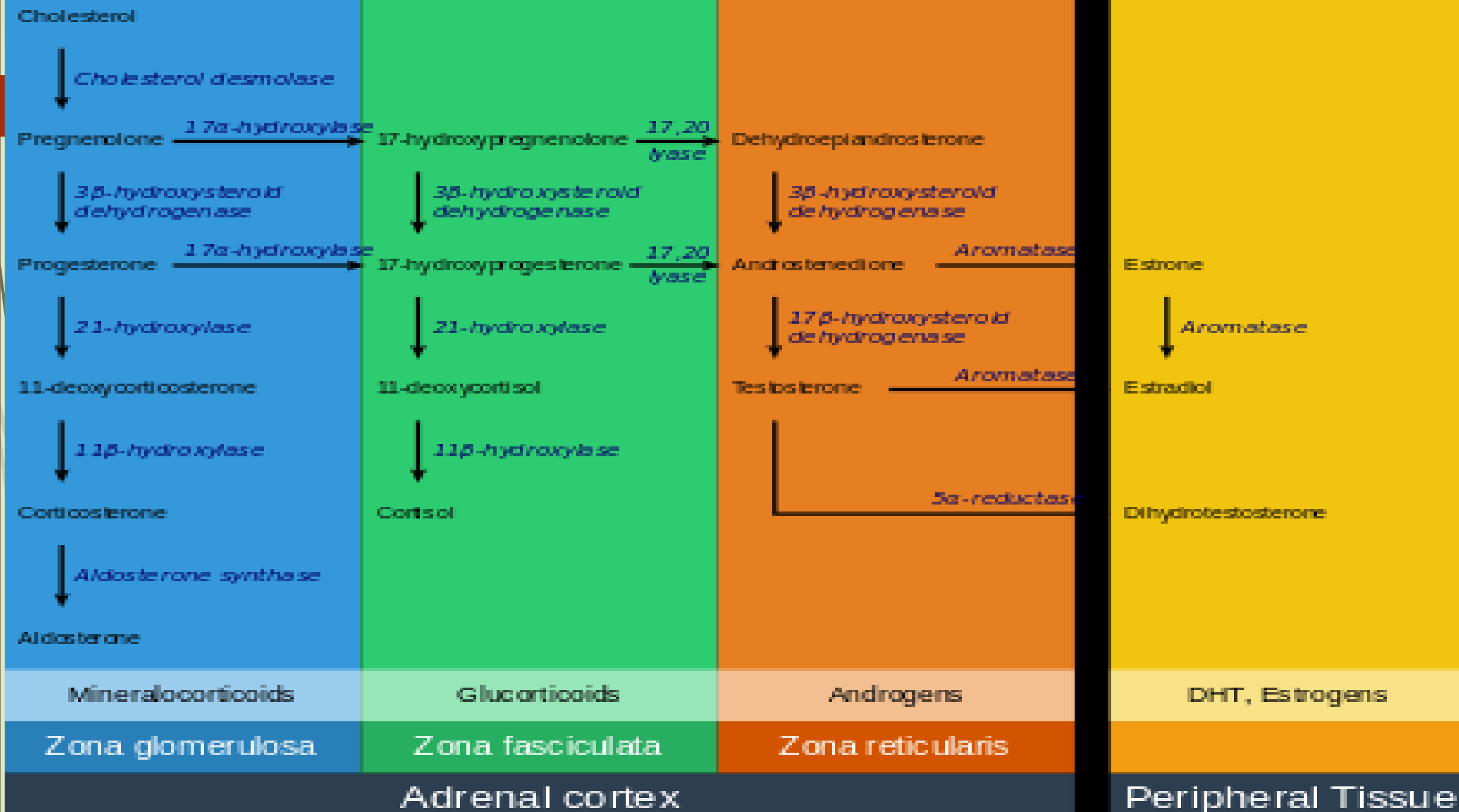
The adrenal gland produces aldosterone, a mineralocorticoid, which is important in the regulation of salt ("mineral") balance and blood volume. In the kidneys, aldosterone acts on the distal convoluted tubules and the collecting ducts by increasing the reabsorption of sodium and the excretion of both potassium and hydrogen ions. Aldosterone is responsible for the reabsorption of about 2% of filtered glomerular filtrate. Sodium retention is also a response of the distal colon and sweat glands to aldosterone receptor stimulation. Angiotensin II and extracellular potassium are the two main regulators of aldosterone production. The amount of sodium present in the body affects the extracellular volume, which in turn influences blood pressure. Therefore, the effects of aldosterone in sodium retention are important for the regulation of blood pressure.

Glucocorticoids

Cortisol is the main glucocorticoid in humans. In species that do not create cortisol, this role is played by corticosterone instead. Glucocorticoids have many effects on metabolism. As their name suggests, they increase the circulating level of glucose. This is the result of an increase in the mobilization of amino acids from protein and the stimulation of synthesis of glucose from these amino acids in the liver. In addition, they increase the levels of free fatty acids, which cells can use as an alternative to glucose to obtain energy. Glucocorticoids also have effects unrelated to the regulation of blood sugar levels, including the suppression of the immune system and a potent anti-inflammatory effect. Cortisol reduces the capacity of osteoblasts to produce new bone tissue and decreases the absorption of calcium in the gastrointestinal tract.

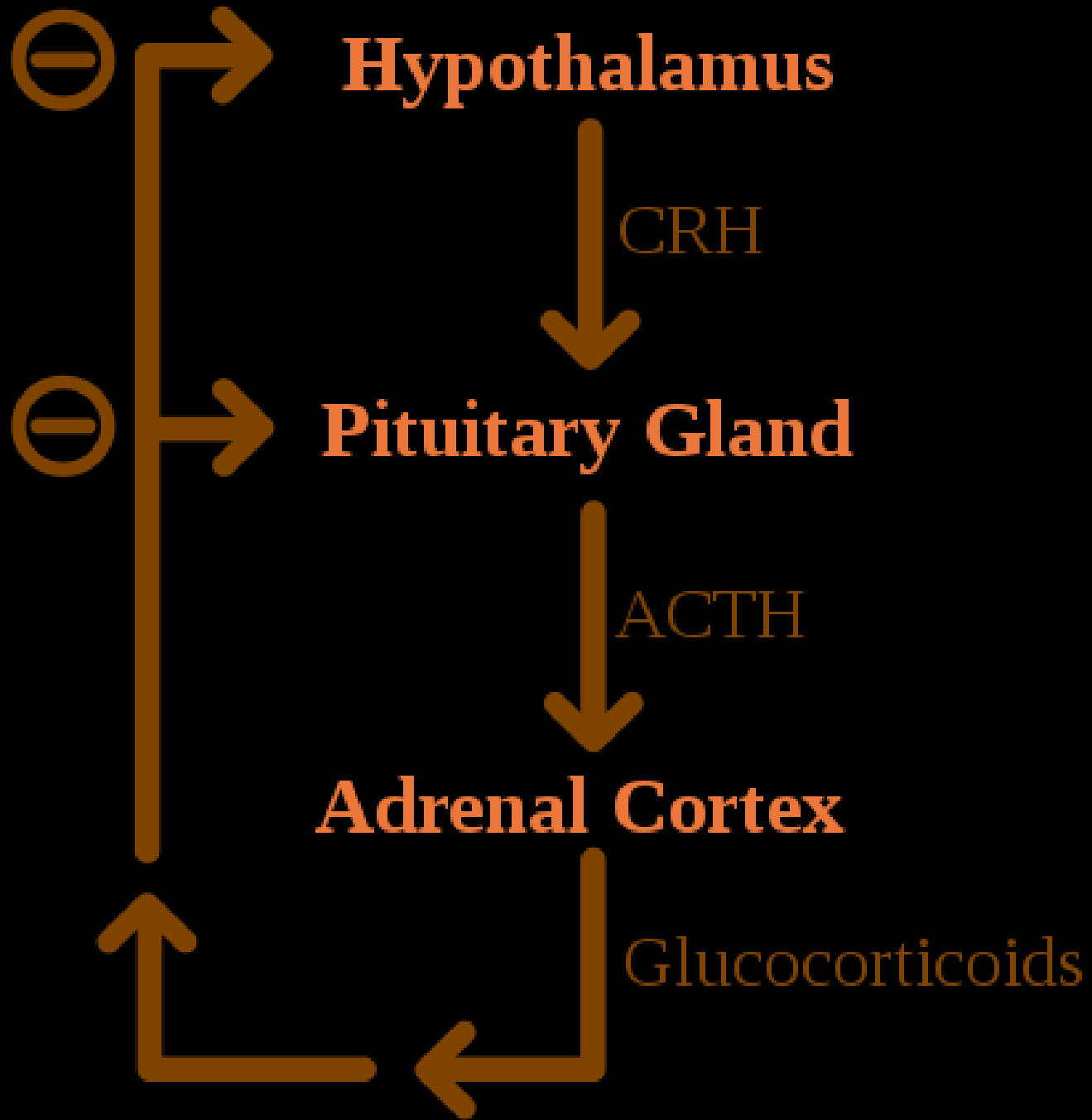


The adrenal gland secretes a basal level of cortisol but can also produce bursts of the hormone in response to adrenocorticotrophic hormone (ACTH) from the anterior pituitary. Cortisol is not evenly released during the day – its concentrations in the blood are highest in the early morning and lowest in the evening as a result of the circadian rhythm of ACTH secretion. Cortisone is an inactive product of the action of the enzyme 11β -HSD on cortisol. The reaction catalyzed by 11β -HSD is reversible, which means that it can turn administered cortisone into cortisol, the biologically active hormone.



Formation: Steroidogenesis in the adrenal glands – different steps occur in different layers of the gland

All corticosteroid hormones share cholesterol as a common precursor. Therefore, the first step in steroidogenesis is cholesterol uptake or synthesis. Cells that produce steroid hormones can acquire cholesterol through two paths. The main source is through dietary cholesterol transported via the blood as cholesterol esters within low density lipoproteins (LDL). LDL enters the cells through receptor-mediated endocytosis. The other source of cholesterol is synthesis in the cell's endoplasmic reticulum. Synthesis can compensate when LDL levels are abnormally low. In the lysosome, cholesterol esters are converted to free cholesterol, which is then used for steroidogenesis or stored in the cell




**Negative
feedback in
the HPA axis**


Regulation

Negative feedback in the HPA axis

Glucocorticoids are under the regulatory influence of the hypothalamus-pituitary-adrenal (HPA) axis. Glucocorticoid synthesis is stimulated by adrenocorticotrophic hormone (ACTH), a hormone released into the bloodstream by the anterior pituitary. In turn, production of ACTH is stimulated by the presence of corticotropin-releasing hormone (CRH), which is released by neurons of the hypothalamus. ACTH acts on the adrenal cells first by increasing the levels of StAR within the cells, and then of all steroidogenic P450 enzymes. The HPA axis is an example of a negative feedback system, in which cortisol itself acts as a direct inhibitor of both CRH and ACTH synthesis. The HPA axis also interacts with the immune system through increased secretion of ACTH at the presence of certain molecules of the inflammatory response



Mineralocorticoid secretion is regulated mainly by the renin–angiotensin–aldosterone system (RAAS), the concentration of potassium, and to a lesser extent the concentration of ACTH. Sensors of blood pressure in the juxtaglomerular apparatus of the kidneys release the enzyme renin into the blood, which starts a cascade of reactions that lead to formation of angiotensin II. Angiotensin receptors in cells of the zona glomerulosa recognize the substance, and upon binding they stimulate the release of aldosterone.



Catecholamines

Primarily referred to in the United States as epinephrine and norepinephrine, adrenaline and noradrenaline are catecholamines, water-soluble compounds that have a structure made of a catechol group and an amine group. The adrenal glands are responsible for most of the adrenaline that circulates in the body, but only for a small amount of circulating noradrenaline. These hormones are released by the adrenal medulla, which contains a dense network of blood vessels. Adrenaline and noradrenaline act at adrenoceptors throughout the body, with effects that include an increase in blood pressure and heart rate. actions of adrenaline and noradrenaline are responsible for the fight or flight response, characterised by a quickening of breathing and heart rate, an increase in blood pressure, and constriction of blood vessels in many parts of the body.

Formation

Catecholamines are produced in chromaffin cells in the medulla of the adrenal gland, from tyrosine, a non-essential amino acid derived from food or produced from phenylalanine in the liver.

Glucocorticoids produced in the adrenal cortex stimulate the synthesis of catecholamines by increasing the levels of tyrosine hydroxylase and PNMT.

Catecholamine release is stimulated by the activation of the sympathetic nervous system. Splanchnic nerves of the sympathetic nervous system innervate the medulla of the adrenal gland. When activated, it evokes the release of catecholamines from the storage granules by stimulating the opening of calcium channels in the cell membrane.

Androgens

Cells in zona reticularis of the adrenal glands produce male sex hormones, or androgens, the most important of which is DHEA. In general, these hormones do not have an overall effect in the male body, and are converted to more potent androgens such as testosterone and DHT or to estrogens (female sex hormones) in the gonads, acting in this way as a metabolic intermediate

HISTOLOGY OF ADRENAL GLAND

Cortex

Adrenal cortex tissue is derived from the intermediate mesoderm. It first appears 33 days after fertilization, shows steroid hormone production capabilities by the eighth week and undergoes rapid growth during the first trimester of pregnancy. The fetal adrenal cortex is different from its adult counterpart, as it is composed of two distinct zones: the inner "fetal" zone, which carries most of the hormone-producing activity, and the outer "definitive" zone, which is in a proliferative phase. The fetal zone produces large amounts of adrenal androgens (male sex hormones) that are used by the placenta for estrogen biosynthesis.

Cortical development of the adrenal gland is regulated mostly by ACTH, a hormone produced by the pituitary gland that stimulates cortisol synthesis. During mid-gestation, the fetal zone occupies most of the cortical volume and produces 100–200 mg/day of DHEA-S, an androgen and precursor of both androgens and estrogens (female sex hormones). Adrenal hormones, especially glucocorticoids such as cortisol, are essential for prenatal development of organs, particularly for the maturation of the lungs. The adrenal gland decreases in size after birth because of the rapid disappearance of the fetal zone, with a corresponding decrease in androgen secretion.

Medulla

The adrenal medulla is derived from neural crest cells, which come from the ectoderm layer of the embryo. These cells migrate from their initial position and aggregate in the vicinity of the dorsal aorta, a primitive blood vessel, which activates the differentiation of these cells through the release of proteins known as BMPs. These cells then undergo a second migration from the dorsal aorta to form the adrenal medulla and other organs of the sympathetic nervous system. Cells of the adrenal medulla are called chromaffin cells because they contain granules that stain with chromium salts, a characteristic not present in all sympathetic organs. Glucocorticoids produced in the adrenal cortex were once thought to be responsible for the differentiation of chromaffin cells. More recent research suggests that BMP-4 secreted in adrenal tissue is the main responsible for this, and that glucocorticoids only play a role in the subsequent development of the cells.

Clinical significance

The normal function of the adrenal gland may be impaired by conditions such as infections, tumors, genetic disorders and autoimmune diseases, or as a side effect of medical therapy. These disorders affect the gland either directly (as with infections or autoimmune diseases) or as a result of the dysregulation of hormone production (as in some types of Cushing's syndrome) leading to an excess or insufficiency of adrenal hormones and the related symptoms.

Cushing's syndrome

Cushing's syndrome is the manifestation of glucocorticoid excess. It can be the result of a prolonged treatment with glucocorticoids or be caused by an underlying disease which produces alterations in the HPA axis or the production of cortisol. Causes can be further classified into ACTH-dependent or ACTH-independent. The most common cause of endogenous Cushing's syndrome is a pituitary adenoma which causes an excessive production of ACTH. The disease produces a wide variety of signs and symptoms which include obesity, diabetes, increased blood pressure, excessive body hair (hirsutism), osteoporosis, depression, and most distinctively, stretch marks in the skin, caused by its progressive thinning

Primary aldosteronism

When the zona glomerulosa produces excess aldosterone, the result is primary aldosteronism. Causes for this condition are bilateral hyperplasia (excessive tissue growth) of the glands, or aldosterone-producing adenomas (a condition called Conn's syndrome). Primary aldosteronism produces hypertension and electrolyte imbalance, increasing potassium depletion sodium retention

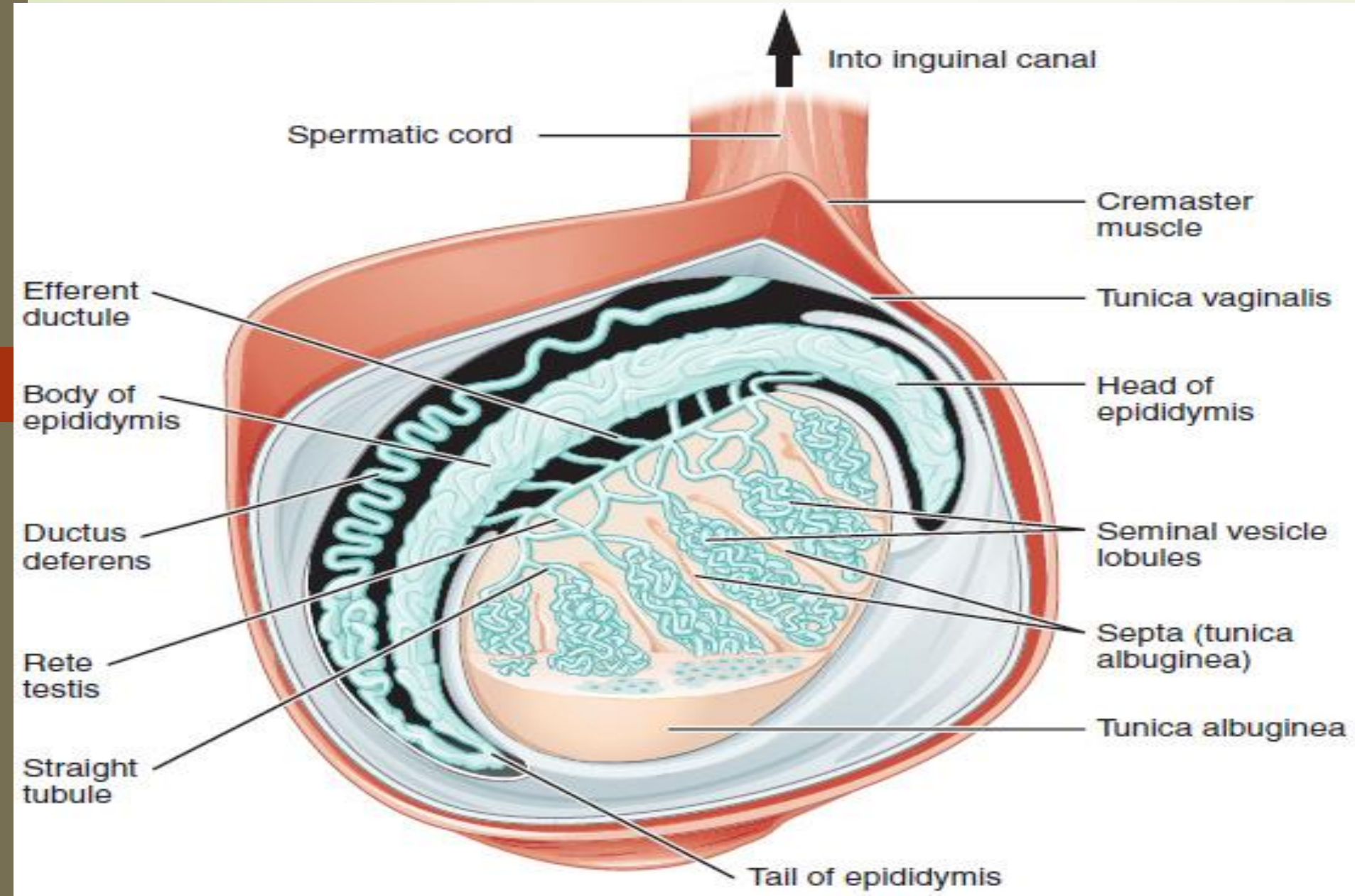
Addison's disease


Characteristic skin hyperpigmentation in Addison's disease

Addison's disease refers to primary hypoadrenalism, which is a deficiency in glucocorticoid and mineralocorticoid production by the adrenal gland. In the Western world, Addison's disease is most commonly an autoimmune condition, in which the body produces antibodies against cells of the adrenal cortex. Worldwide, the disease is more frequently caused by infection, especially from tuberculosis. A distinctive feature of Addison's disease is hyperpigmentation of the skin, which presents with other nonspecific symptoms such as fatigue.

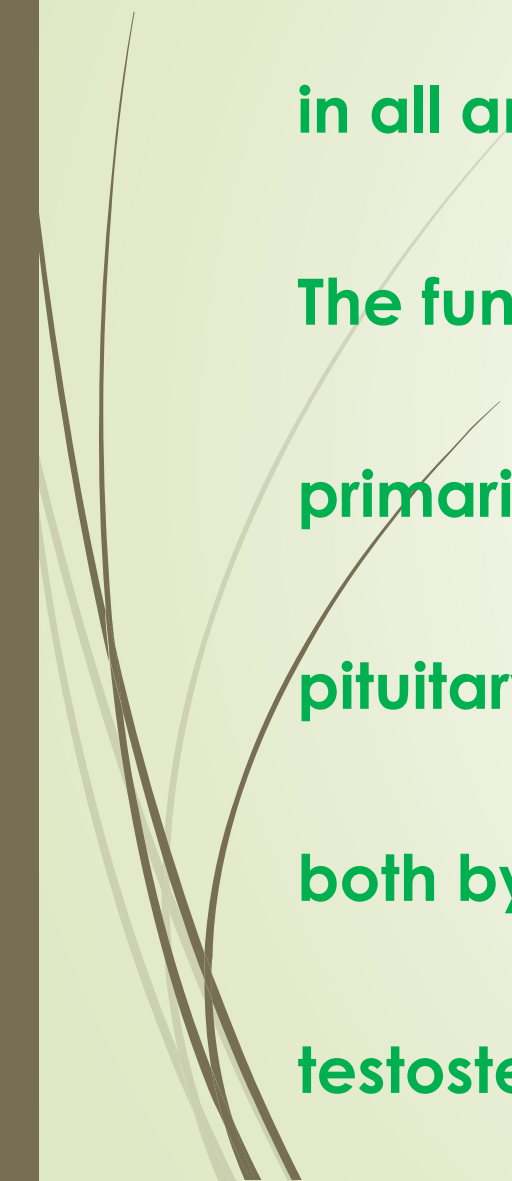
BRIEF ACCOUNT OF STRUCTURAL FEATURES HISTOLOGICAL STRUCTURE AND FUNCTION OF GONADS: MALE GONAD OR TESTIS

Diagram of inner structures of testicle





Testicle or testis (plural testes) is the male reproductive gland or gonad in all animals, including humans. It is homologous to the female ovary. The functions of the testes are to produce both sperm and androgens, primarily testosterone. Testosterone release is controlled by the anterior pituitary luteinizing hormone; whereas sperm production is controlled both by the anterior pituitary follicle-stimulating hormone and gonadal testosterone.



Structure

Male gonad (testes, left) and female gonad (ovaries, right)

Males have two testicles of similar size contained within the scrotum, which is an extension of the abdominal wall. Scrotal asymmetry is not unusual: one testicle extends farther down into the scrotum than the other due to differences in the anatomy of the vasculature.

Measurement

The volume of the testicle can be estimated by palpating it and comparing it to ellipsoids of known sizes. Another method is to use calipers (an orchidometer) or a ruler either on the person or on an ultrasound image to obtain the three measurements of the x, y, and z axes (length, depth and width). These measurements can then be used to calculate the volume, using the formula for the volume of an ellipsoid:

Internal structure

Transverse section through the left side of the scrotum and the left testis.

Duct system

The testes are covered by a tough membranous shell called the tunica albuginea. Within the testes are very fine coiled tubes called seminiferous tubules. The tubules are lined with a layer of cells (germ cells) that develop from puberty through old age into sperm cells (also known as spermatozoa or male gametes). The developing sperm travel through the seminiferous tubules to the rete testis located in the mediastinum testis, to the efferent ducts, and then to the epididymis where newly created sperm cells mature (see spermatogenesis). The sperm move into the vas deferens, and are eventually expelled through the urethra and out of the urethral orifice through muscular contractions.

Primary cell types

Within the seminiferous tubules

Here, germ cells develop into spermatogonia, spermatocytes, spermatids and spermatozoon through the process of spermatogenesis. The gametes contain DNA for fertilization of an ovum

Sertoli cells – the true epithelium of the seminiferous epithelium, critical for the support of germ cell development into spermatozoa. Sertoli cells secrete inhibin.

Peritubular myoid cells surround the seminiferous tubules.

Between tubules (interstitial cells)

Between tubules (interstitial cells)

Leydig cells – cells localized between seminiferous tubules that produce and secrete testosterone and other androgens important for sexual development and puberty, secondary sexual characteristics like facial hair, sexual behavior and libido, supporting spermatogenesis and erectile function. Testosterone also controls testicular volume.

Also present are:

Immature Leydig cells

Interstitial macrophages and epithelial cells.

Blood supply and lymphatic drainage

Blood supply and lymphatic drainage of the testes and scrotum are distinct:

The paired testicular arteries arise directly from the abdominal aorta and descend through the inguinal canal, while the scrotum and the rest of the external genitalia is supplied by the internal pudendal artery (itself a branch of the internal iliac artery).

The testis has collateral blood supply from 1. the cremasteric artery (a branch of the inferior epigastric artery, which is a branch of the external iliac artery), and 2. the artery to the ductus deferens (a branch of the inferior vesical artery, which is a branch of the internal iliac artery). Therefore, if the testicular artery is ligated, e.g., during a Fowler-Stevens orchiopexy for a high undescended testis, the testis will usually survive on these other blood supplies.

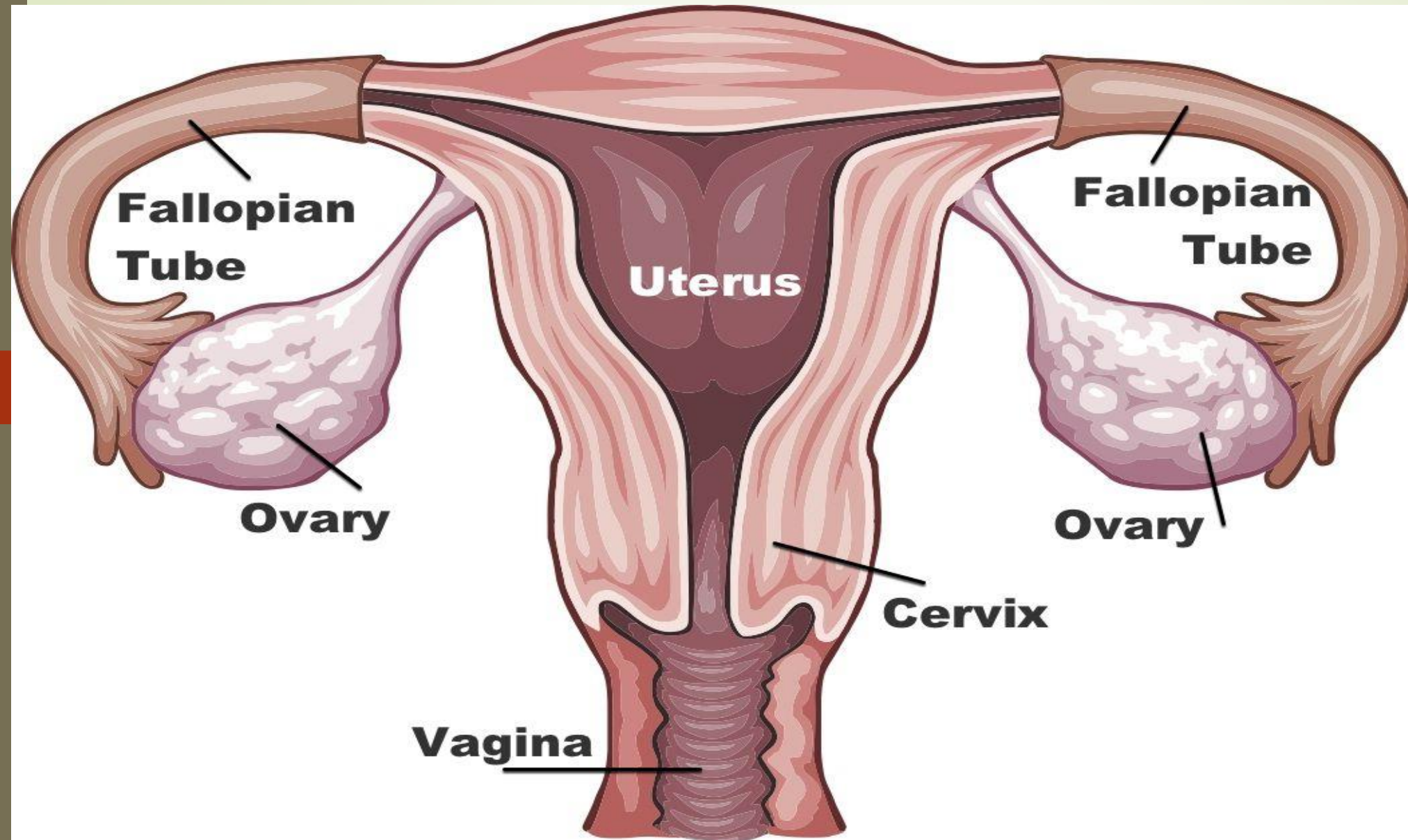
Lymphatic drainage of the testes follows the testicular arteries back to the paraaortic lymph nodes, while lymph from the scrotum drains to the inguinal lymph nodes.

Layers: Layers of the Scrotum.ogv

3D anatomy of the layers surrounding the testis.

Many anatomical features of the adult testis reflect its developmental origin in the abdomen. The layers of tissue enclosing each testicle are derived from the layers of the anterior abdominal wall. Notably, the cremasteric muscle arises from the internal oblique muscle.

FEMALE GONAD OR OOVERIES



The female gonads are called the ovaries. In this article, we will initially look at the basic function, location, components and clinical significance of the ovaries. The latter part of the article will cover the ligaments associated with the ovaries and their vasculature, lymphatic drainage and innervation.

In both the males and females, the gonads develop within the mesonephric ridge and descend through the abdomen. However, unlike the testes, the ovaries stop in the pelvis.


The ovaries are paired, oval organs attached to the posterior surface of the broad ligament of the uterus by the mesovarium (a fold of peritoneum, continuous with the outer surface of the ovaries).

Neurovascular structures enter the hilum of the ovary via the mesovarium.

The main functions of the ovaries are:

To produce oocytes (female gametes) in preparation for fertilization.

To produce the sex steroid hormones estrogen and progesterone, in response to pituitary gonadotrophins (LH and FSH).



The ovary is an organ found in the female reproductive system that produces an ovum. When released, this travels down the fallopian tube into the uterus, where it may become fertilized by a sperm.

There is an ovary (from Latin ovarium 'egg, nut') found on each side of the body. The ovaries also secrete hormones that play a role in the menstrual cycle and fertility. The ovary progresses through many stages beginning in the prenatal period through menopause. It is also an endocrine gland because of the various hormones that it secretes

Structure

The ovaries are considered the female gonads.[2] Each ovary is whitish in color and located alongside the lateral wall of the uterus in a region called the ovarian fossa. The ovarian fossa is the region that is bounded by the external iliac artery and in front of the ureter and the internal iliac artery. This area is about 4 cm x 3 cm x 2 cm in size.

The ovaries are surrounded by a capsule, and have an outer cortex and an inner medulla. The capsule is of dense connective tissue and is known as the tunica albuginea.

Usually, ovulation occurs in one of the two ovaries releasing an egg each menstrual cycle.

The side of the ovary closest to the fallopian tube is connected to it by infundibulopelvic ligament, and the other side points downwards attached to the uterus via the ovarian ligament.

Other structures and tissues of the ovaries include the hilum.

Ligaments

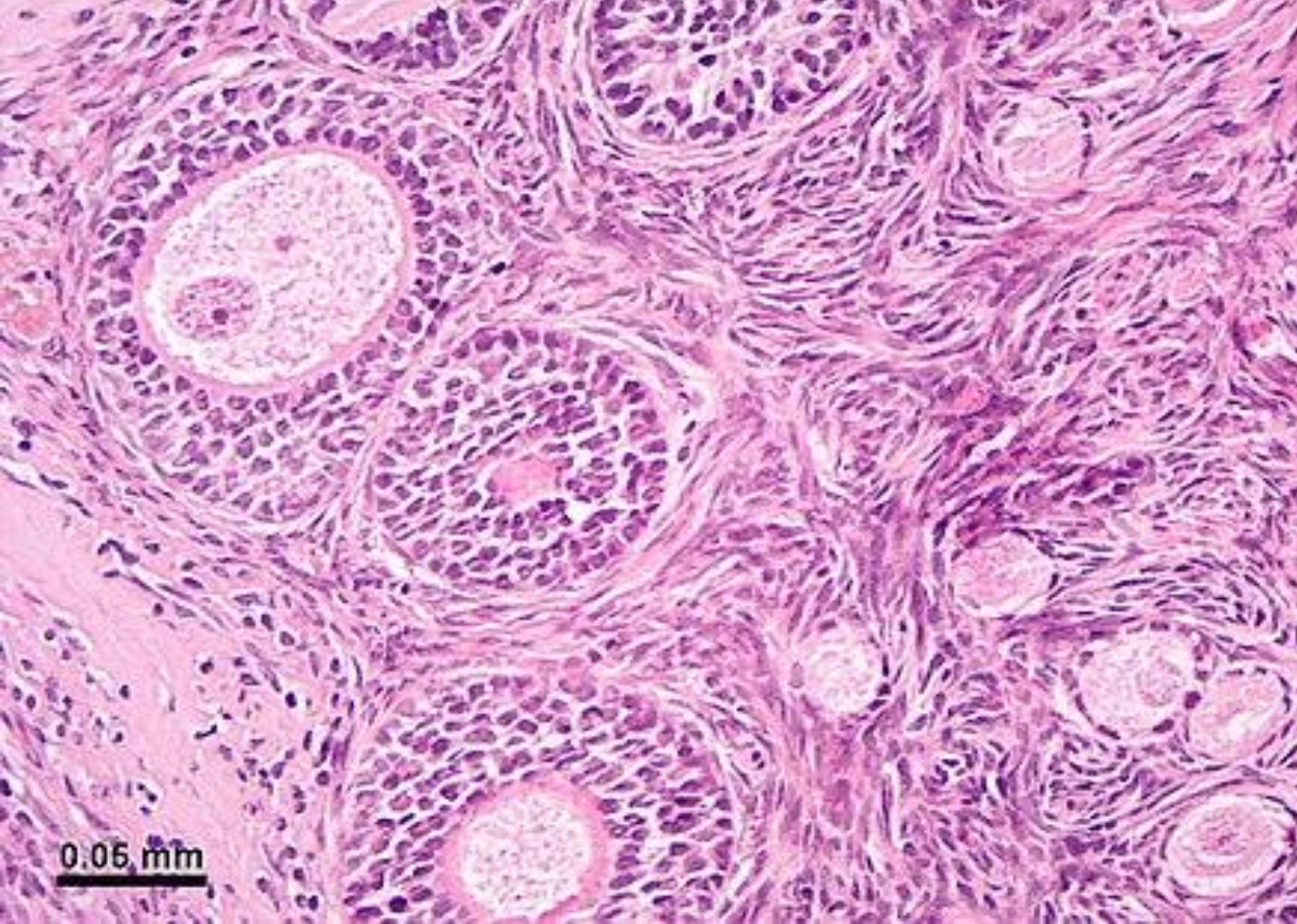
The ovaries lie within the peritoneal cavity, on either side of the uterus, to which they are attached via a fibrous cord called the ovarian ligament.

The ovaries are uncovered in the peritoneal cavity but are tethered to the body wall via the suspensory ligament of the ovary which is a posterior extension of the broad ligament of the uterus. The part of the broad ligament of the uterus that covers the ovary is known as the mesovarium.

MICROANATOMY OR HISTOLOGY

The surface of the ovaries is covered with membrane consisting of a lining of simple cuboidal-to-columnar shaped mesothelium, called the germinal epithelium.

The outer layer is the ovarian cortex, consisting of ovarian follicles and stroma in between them. Included in the follicles are the cumulus oophorus, membrana granulosa (and the granulosa cells inside it), corona radiata, zona pellucida, and primary oocyte. Theca of follicle, antrum and liquor folliculi are also contained in the follicle. Also in the cortex is the corpus luteum derived from the follicles. The innermost layer is the ovarian medulla.[8] It can be hard to distinguish between the cortex and medulla, but follicles are usually not found in the medulla.



Micrograph of the ovarian cortex from a rhesus monkey showing several round follicles embedded in a matrix of stromal cells. A secondary follicle sectioned through the nucleus of an oocyte is at the upper left, and earlier stage follicles are at the lower right. The tissue was stained with the dyes hematoxylin and eosin

Follicular cells are flat epithelial cells that originate from surface epithelium covering the ovary, are surrounded by Granulosa cells - that have changed from flat to cuboidal and proliferated to produce a stratified epithelium

Function

At puberty, the ovary begins to secrete increasing levels of hormones.

Secondary sex characteristics begin to develop in response to the hormones. The ovary changes structure and function beginning at puberty.

Since the ovaries are able to regulate hormones, they also play an important role in pregnancy and fertility. When egg cells (oocytes) are released from the Fallopian tube, a variety of feedback mechanisms stimulate the endocrine system which cause hormone levels to change.

These feedback mechanisms are controlled by the hypothalamus and pituitary gland. Messages from the hypothalamus are sent to the pituitary gland. In turn, the pituitary gland releases hormones to the ovaries. From this signaling, the ovaries release their own hormones.

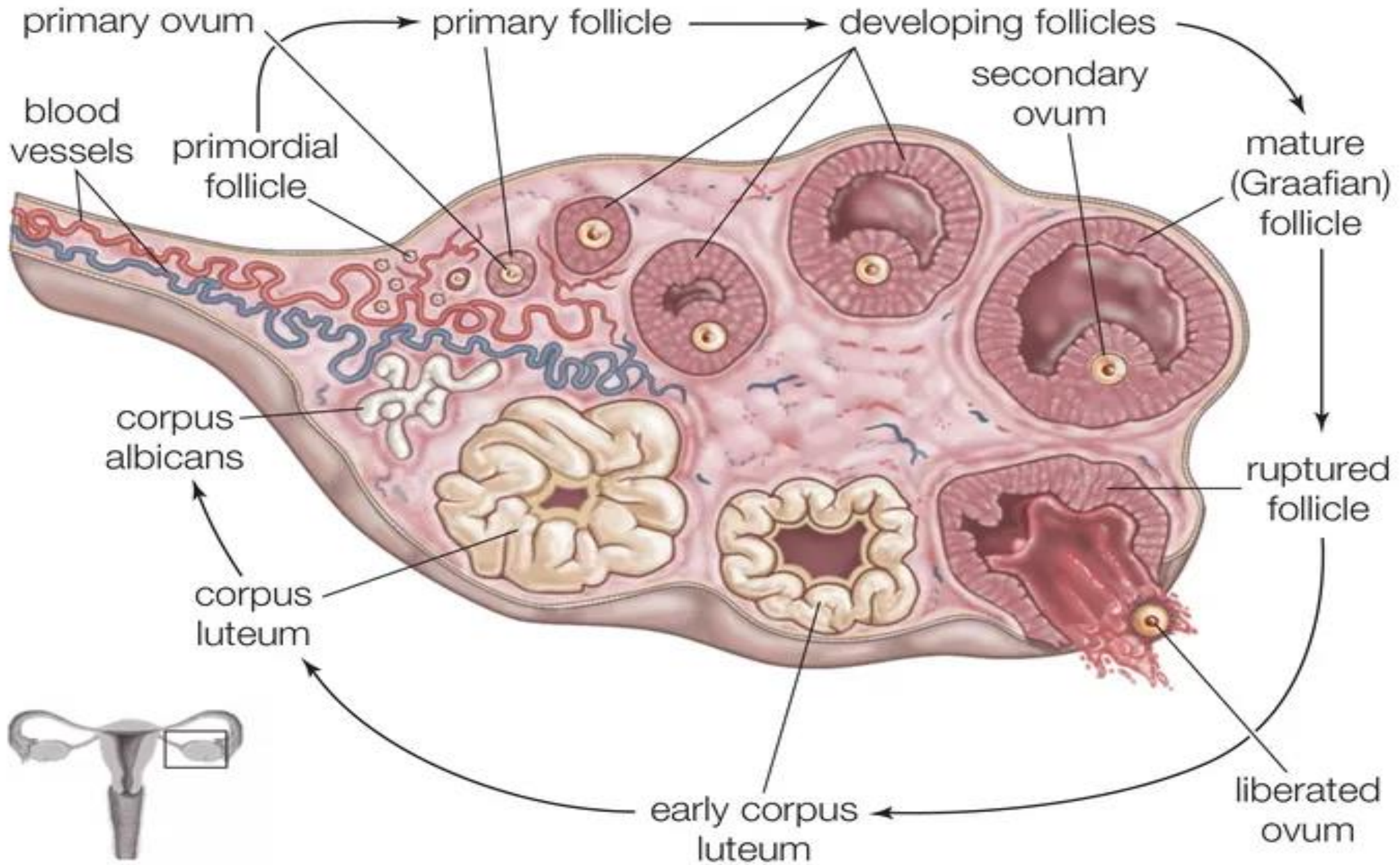
Gamete production: Oogenesis

The ovaries are the site of production and periodical release of egg cells, the female gametes. In the ovaries, the developing egg cells (or oocytes) mature in the fluid-filled

The process of ovulation and gamete production, oogenesis, in a human ovary. follicles. Typically, only one oocyte develops at a time, but others can also mature simultaneously. Follicles are composed of different types and number of cells according to the stage of their maturation, and their size is indicative of the stage of oocyte development.

When the oocyte finishes its maturation in the ovary, a surge of luteinizing hormone secreted by the pituitary gland stimulates the release of the oocyte through the rupture of the follicle, a process called ovulation.[13] The follicle remains functional and reorganizes into a corpus luteum, which secretes progesterone in order to prepare the uterus for an eventual implantation of the embryo.

O O G E N E S I S



Hormone secretion

At maturity, ovaries secrete estrogen, androgen, inhibin, and progesterone.

In women before menopause, 50% of testosterone is produced by the ovaries and released directly into the blood stream. The other 50% of testosterone in the blood stream is made from conversion of the adrenal pre-androgens (DHEA and androstenedione) to testosterone in other parts of the body. Estrogen is responsible for the appearance of secondary sex characteristics for females at puberty and for the maturation and maintenance of the reproductive organs in their mature functional state. Progesterone prepares the uterus for pregnancy, and the mammary glands for lactation. Progesterone functions with estrogen by promoting menstrual cycle changes in the endometrium



**THANK
YOU**